

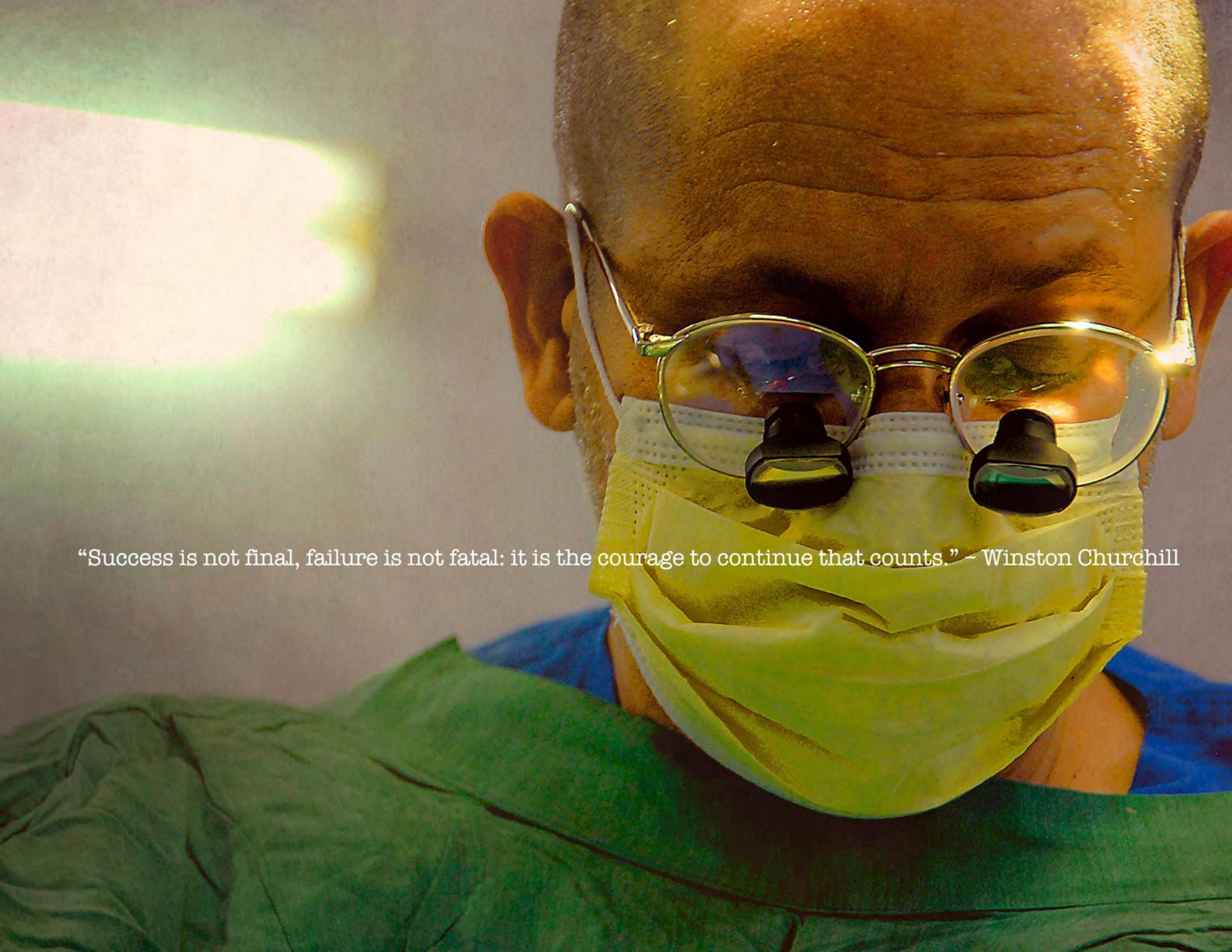
A close-up photograph of a man's face, likely a medical professional, wearing a surgical mask and glasses. A surgical instrument is visible near his ear. The text "Dr. Brian Camazine: A Man on a Mission" is overlaid on the right side of the image.

Dr. Brian Camazine:  
A Man on a Mission









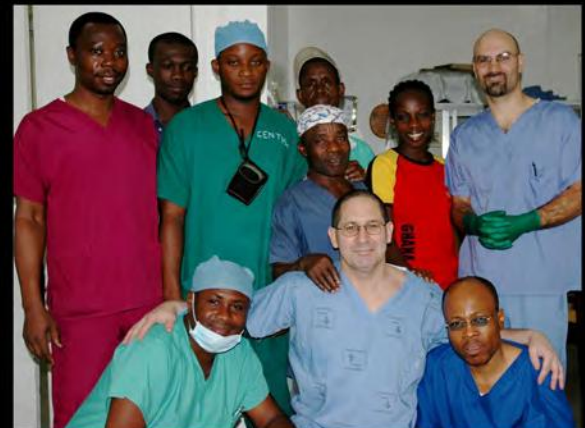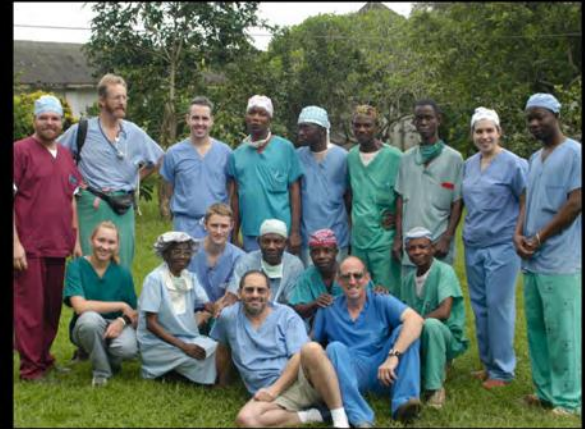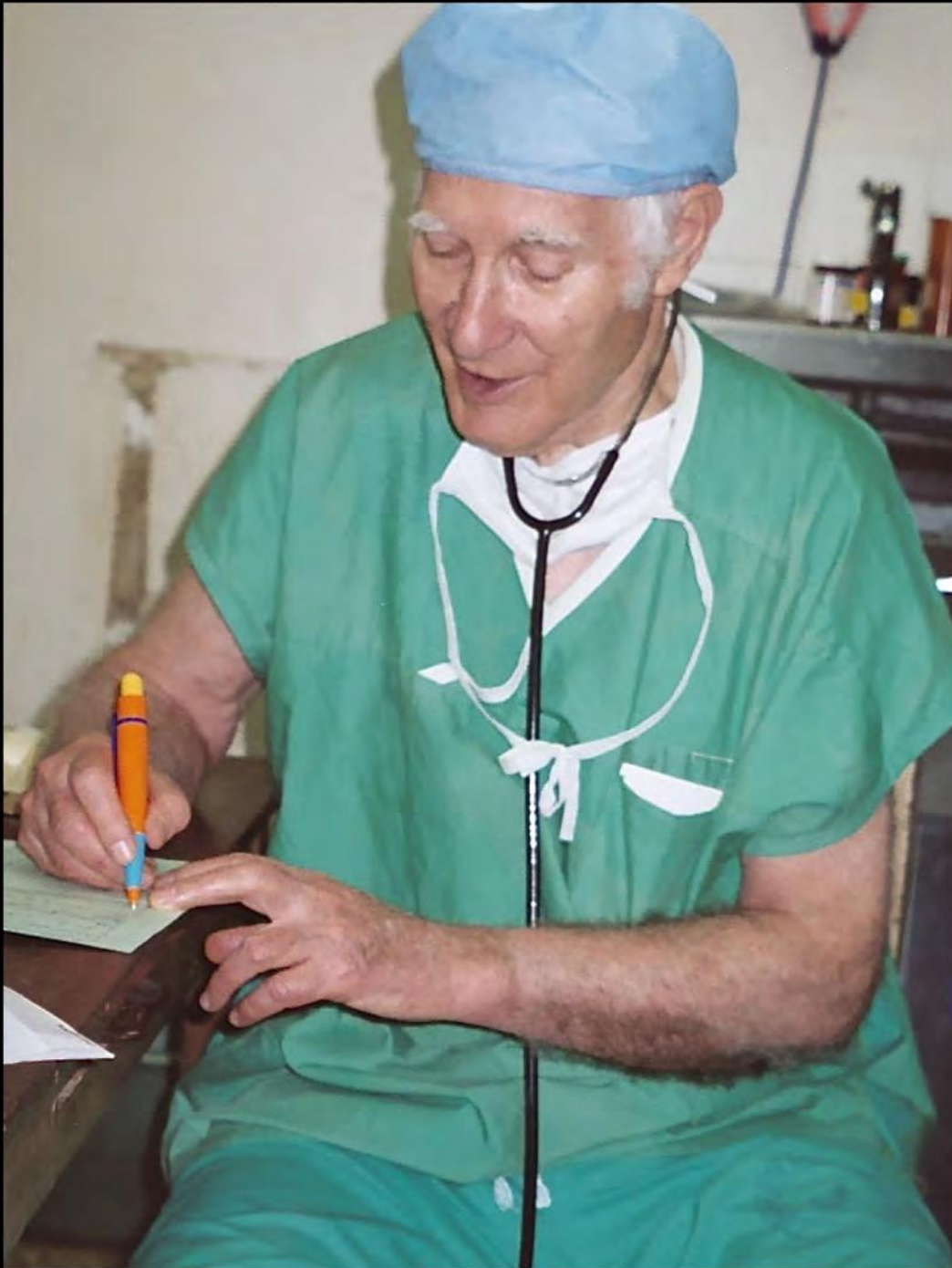"Success is not final, failure is not fatal: it is the courage to continue that counts." - Winston Churchill

# Our History

---

In 1998 , Gbemutor Kama, a Nigerian founded Professionals For Humanity (PROFOH) with Cliff Jarrell an American missionary in West Africa. The official launch was held at the Hotel Presidential, Port Harcourt, Nigeria in May 2000. A few years later they were joined by Mr. Markus von- Have, a German. The organization is now a global non-profit, medical and social humanitarian organization under the 501 status in the United States that is also incorporated in Germany, Ghana, Nepal, Nigeria and South Africa. It has presence in Egypt, Brazil, Italy, Czech Republic, Honduras, Jamaica, Ireland, Benin, Liberia, Cameroon, etc. With the support of partner organizations like Earthwide Surgical Foundation and Medical Mission International, we have performed thousands of surgeries, ,thousands of children immunized against polio across West Africa ,several local scholarships awarded, primary schools renovated ,hundreds of writing desks and safe drinking water provided, more than a million patients have benefited from our clinical consultations and treatments .We are proud to say God has been conducting these surgeries for our organization-some of them can be classified as surgical miracles while others are horrors most of them were performed by Brian Camazine, a professor of surgery including Stuart Quartermont and Gbaranen Gbanaador both also professors in Texas the United States.







“The mass of men lead lives of quiet desperation” – Henry David Thoreau

## Robert

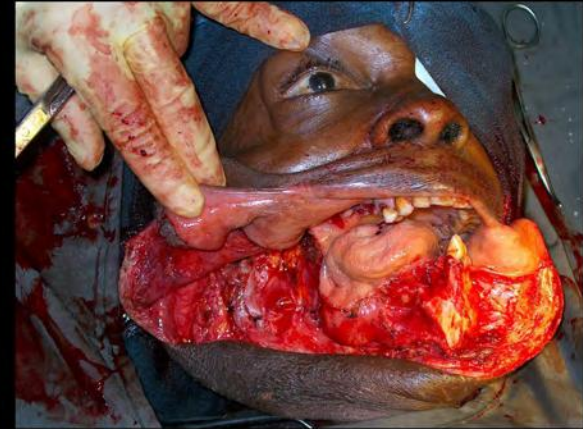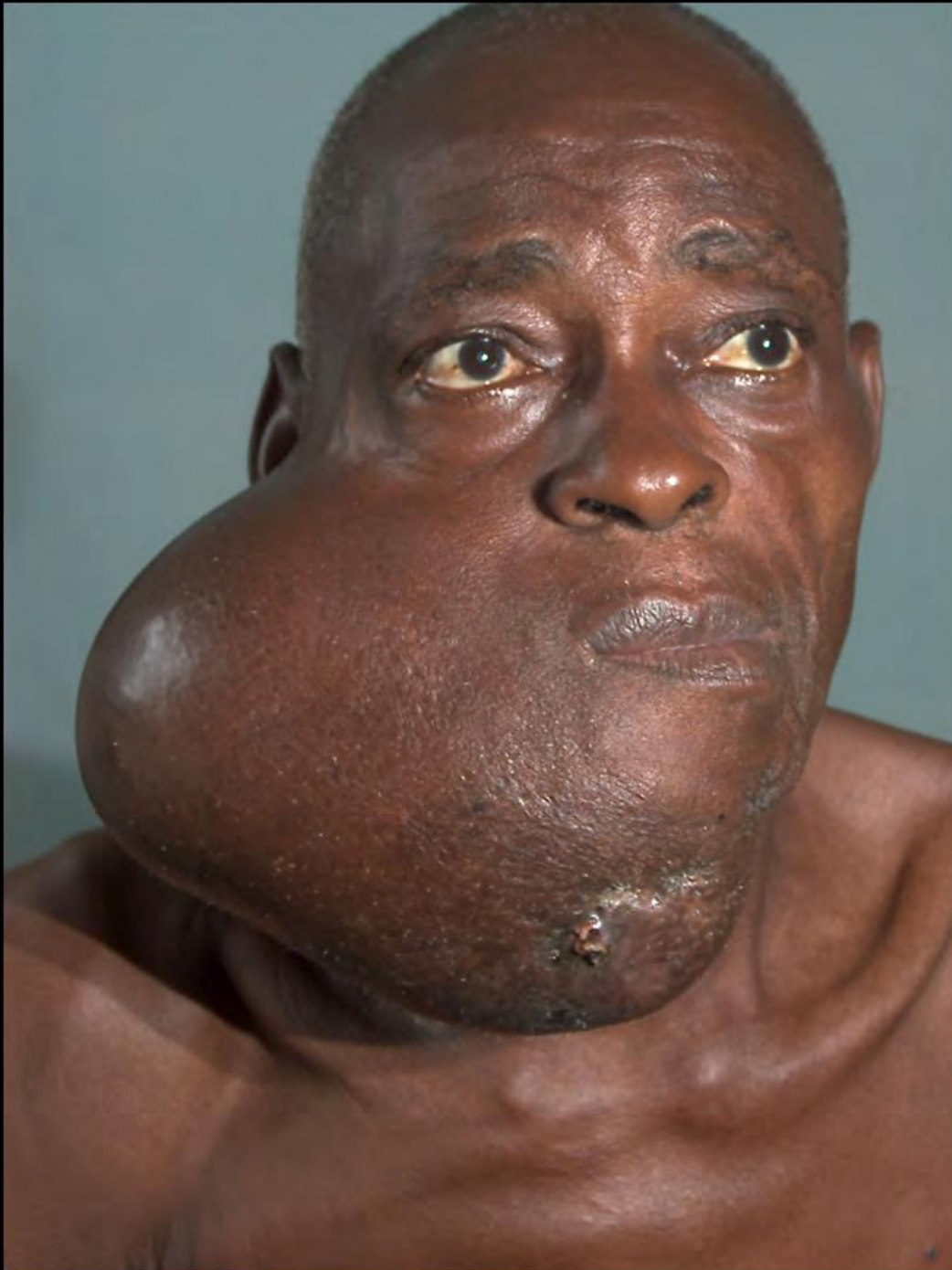---

I first met Robert in 2004. He had a massive jaw tumor that had had been growing for a decade. He had a previous surgery but the tumor recurred and he gave up hope of a cure. The tumor was an ameloblastoma, a tumor of odontogenic origin (referring to teeth formation) that expands the mandible (jaw) from the inside. In Robert’s case, the hollowed out mandible became infected and developed a sinus to the skin (see the lowest portion of the chin). Every time he coughed or sneezed, pus would gush out of the sinus. It was a terrible way to live.

We resected the tumor, which required removing half of his mandible, and did a pectoralis major muscle flap to help with reconstruction and closure. He is still doing well, without recurrence, as of July, 2011.

An interesting aside to this wonderful story is that Robert’s daughter went to medical school. She had financial difficulties and almost had to quit. Our organization supported her till graduation in 2010.







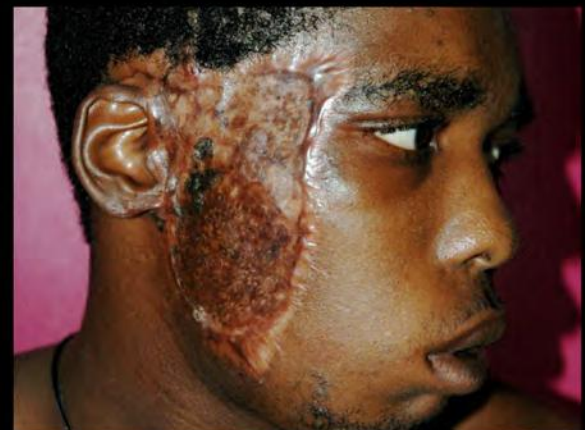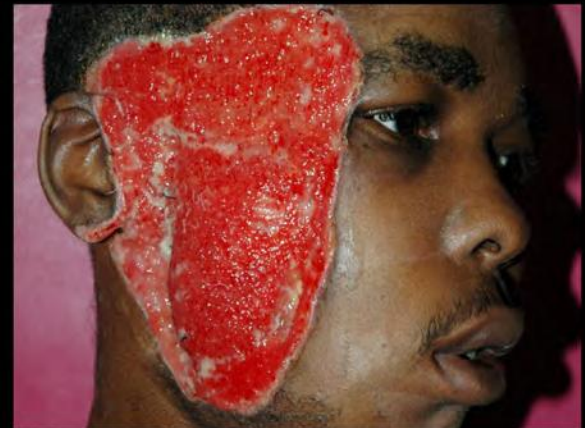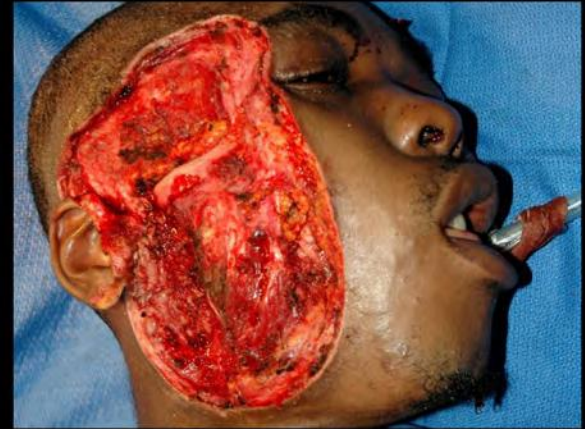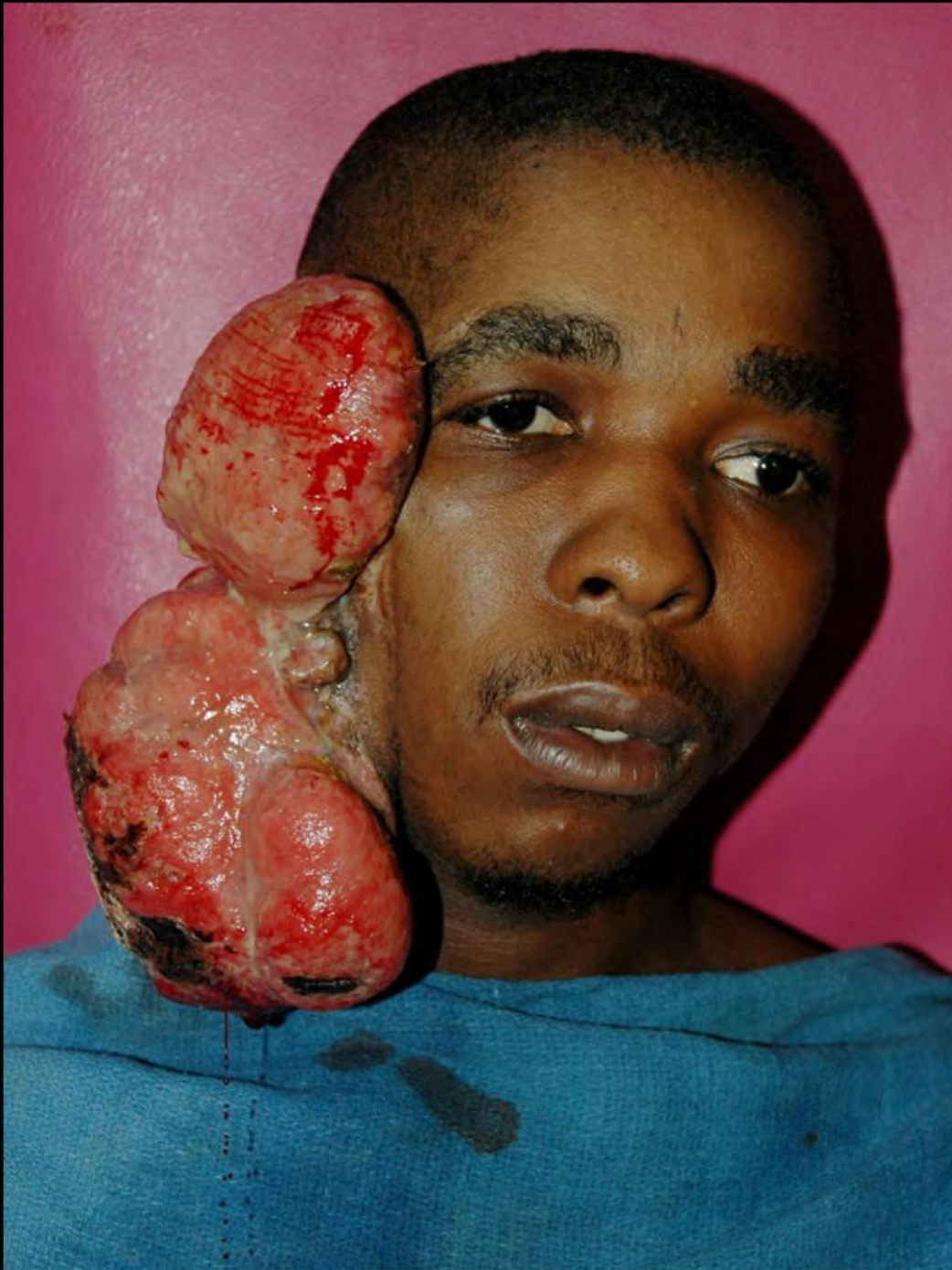# Innocent

---

I met Innocent in February of 2011. He is a young male that had a huge mass growing from the right side of his face for years. He had been to several medical centers but the surgeons refused to operate-either the surgeons lacked the required skills or the patient lacked the required funds. The tumor was quite spectacular. Each time Innocent removed the dressings covering the tumor, blood squirted from the bottom. As a result, Innocent was anemic as well as malnourished (since he had no money for food). For this complicated case, I called in the A-Team-Dr. Mike Enyinnah (a general surgeon and past student of mine). We rapidly removed the tumor and controlled the bleeding. The wound did not start granulating until we bought Innocent 6 eggs per day for two weeks! Then we skin grafted the wound.

The pathology showed a dermatofibrosarcoma protuberans (DFSP)-fibrosarcomatous variant. This tumor is a rare soft tissue sarcoma that is usually not malignant but tends to recur locally-especially if the surgical margins are close to the tumor. The fibrosarcomatous variant is more malignant. Unfortunately for Innocent, the margins were very close (since we could not remove his head) and the pathology worrisome. As a result, he will need radiation therapy. Of course, radiation therapy is difficult in Nigeria. There are only 2-3 sites that do this treatment and it is costly. Innocent will have to travel to Zaria, in Northern Nigeria, which is over 500 miles from NCH. Earthwide Surgical Foundation will pay for his treatment.







“I don’t know what it is, but it’s the worst case I’ve ever seen.” – Brian Camazine, MD

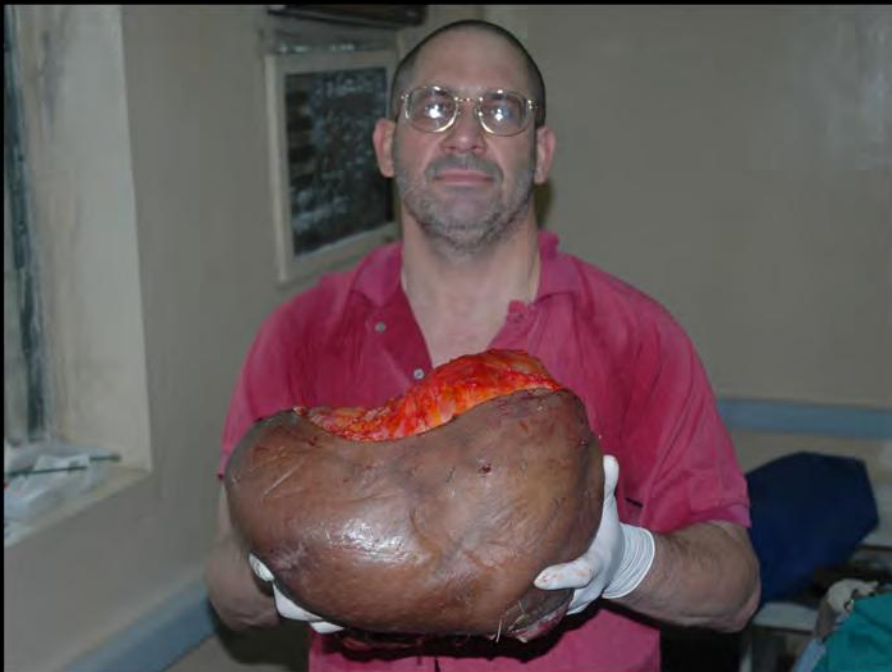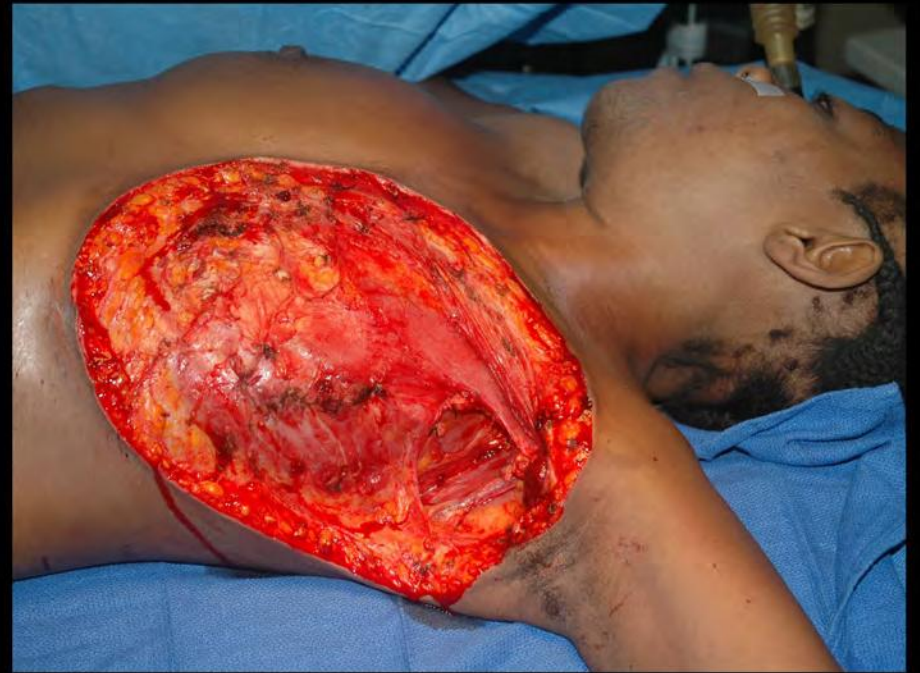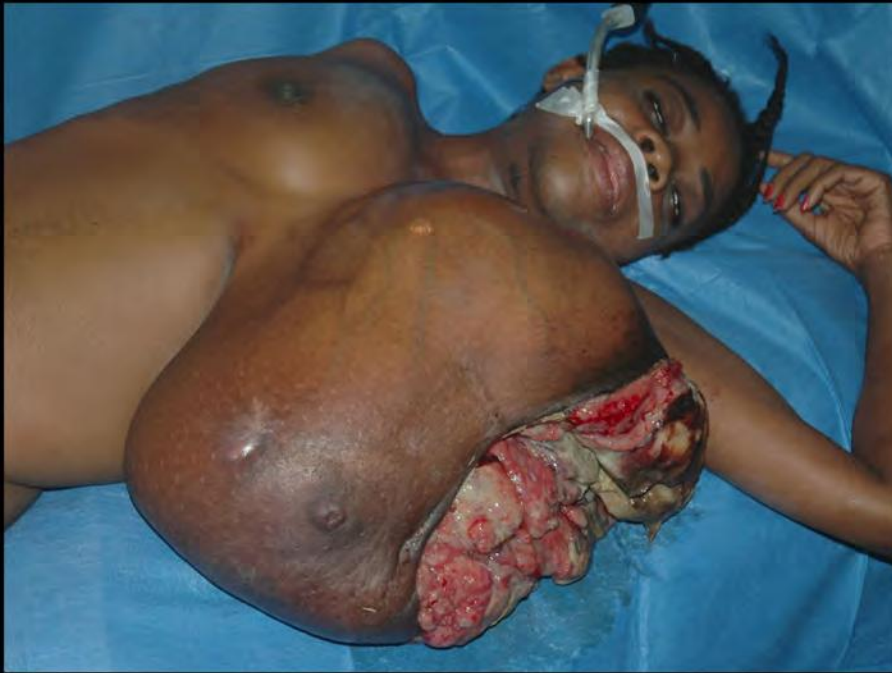## Ogechi

---

When I first saw Ogechi in June, 2006, she was lying in bed, with a shawl covering her upper chest, and I thought she was nursing a baby. She had a enormous left breast mass that was sucking the life out of her. She was too weak to walk. She had surgery previously and when the tumor recurred, she gave up.

It was obvious that resecting the tumor would be challenging. The veins feeding it were bigger than my thumb. I called in Dr. Mike Enyinnah and we braced for battle. I had planned to slowly remove the tumor and keep the bleeding under control. But as Helmuth von Moltke the Elder stated “No battle plan survives contact with the enemy”. The bleeding was so fierce that it was audible. Finally, we just took a scalpel and cut off the tumor as fast as possible. Then we compressed the wound and the bleeding stopped! After several weeks, the wound was granulating well and we placed a skin graft. Ogechi came back 6 months later and had gained about 35 pounds. She was so thankful.

The pathology showed cystosarcoma phylloides which is generally a benign sarcoma of the breast. Ogechi had radiation therapy after surgery and remains tumor free





# Ucheria

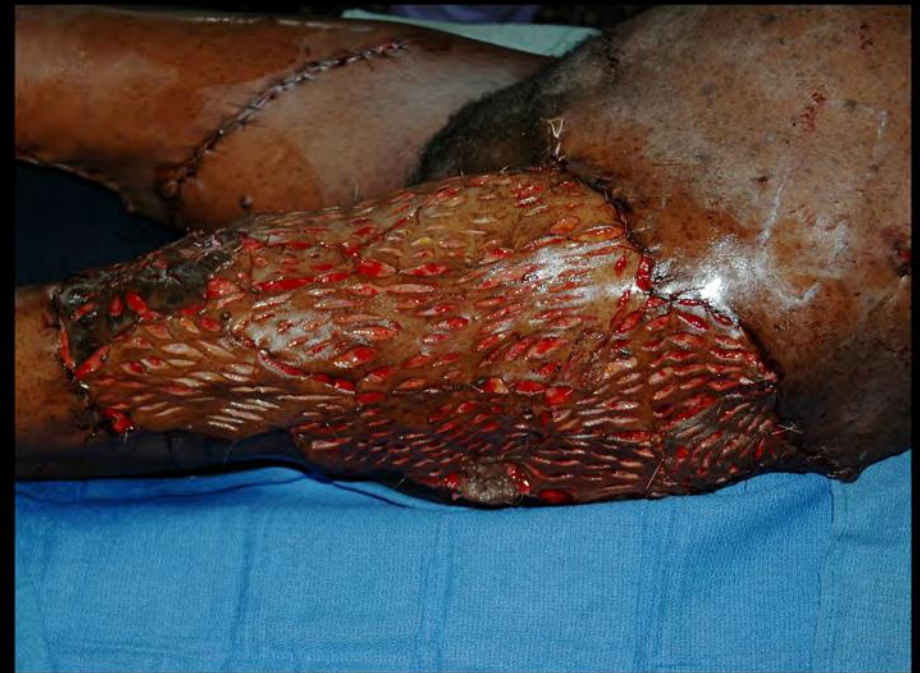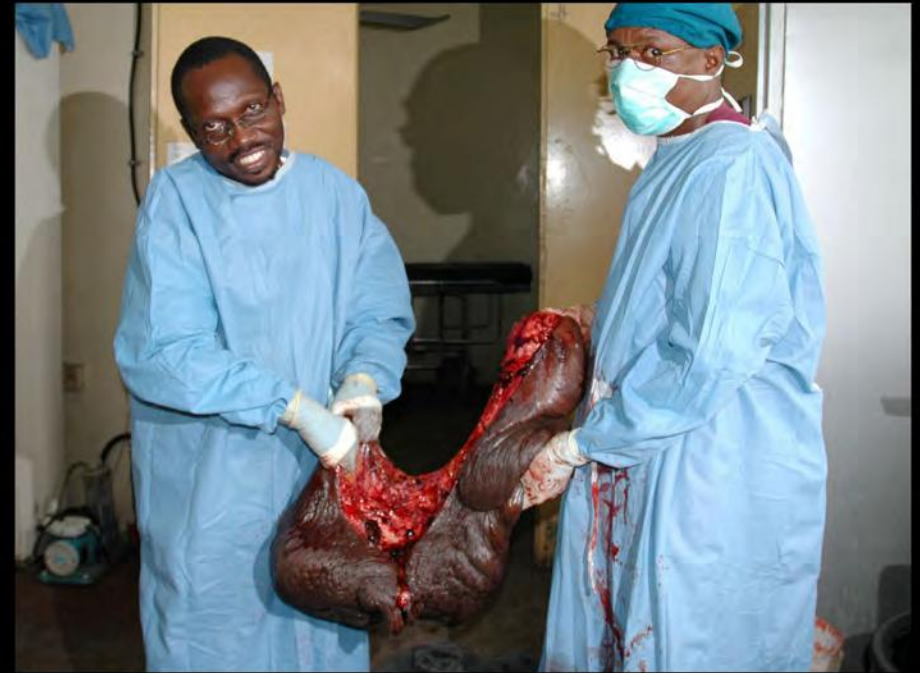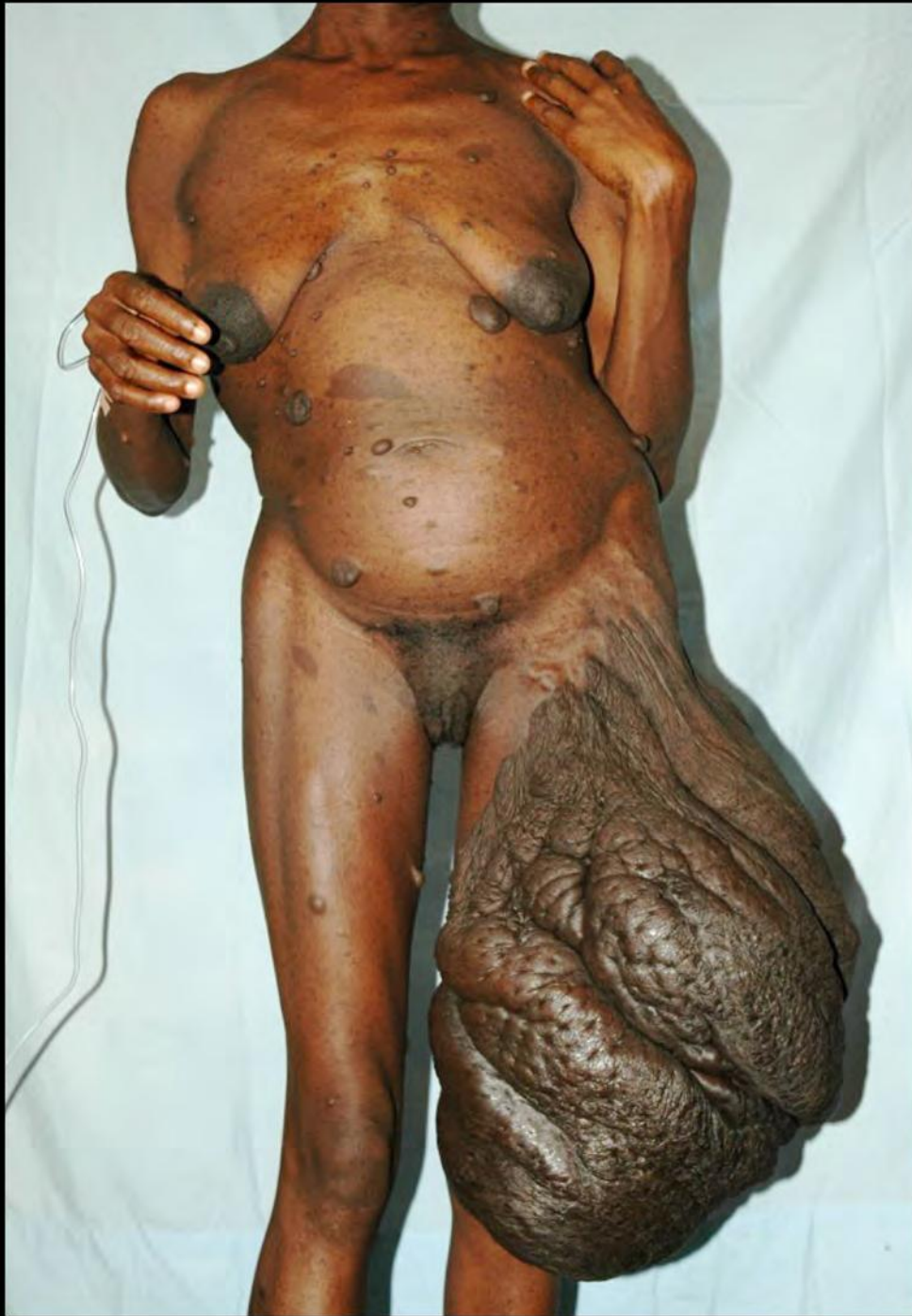---

As soon as Ucheria limped into the operating room for consultation in 2008, I knew from the unusual bulge on her hip that there was something terrible lurking under her clothes. When she dropped her wrap, my jaw dropped as well. Her tumor gave new meaning to “excess baggage”. She had neurofibromatosis! In fact, it was the worst case I had ever seen!

Dr. Mike Enyinnah and Dr. Uche Nkeonye assisted me in the surgery. We had to put two operating tables together to do her surgery. At surgery, it took 4 people just to move the tumor around so it could be removed. We finally separated the tumor from her body and it took two people to carry it out of the operating room. What a workout! After her hip and leg started granulating, we covered the wound with a skin graft.

She recovered without complications. Later we learned that she became pregnant and died three years later during childbirth.





# Joshua

---

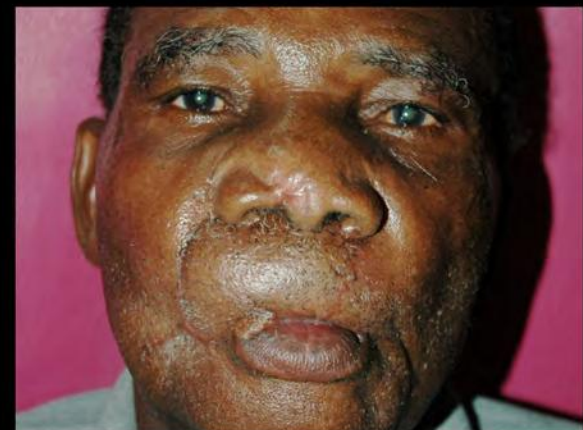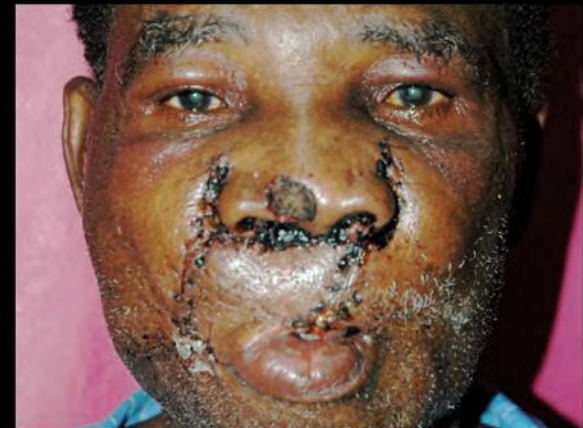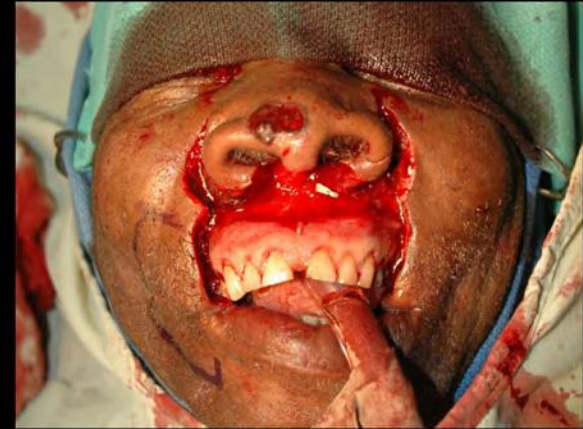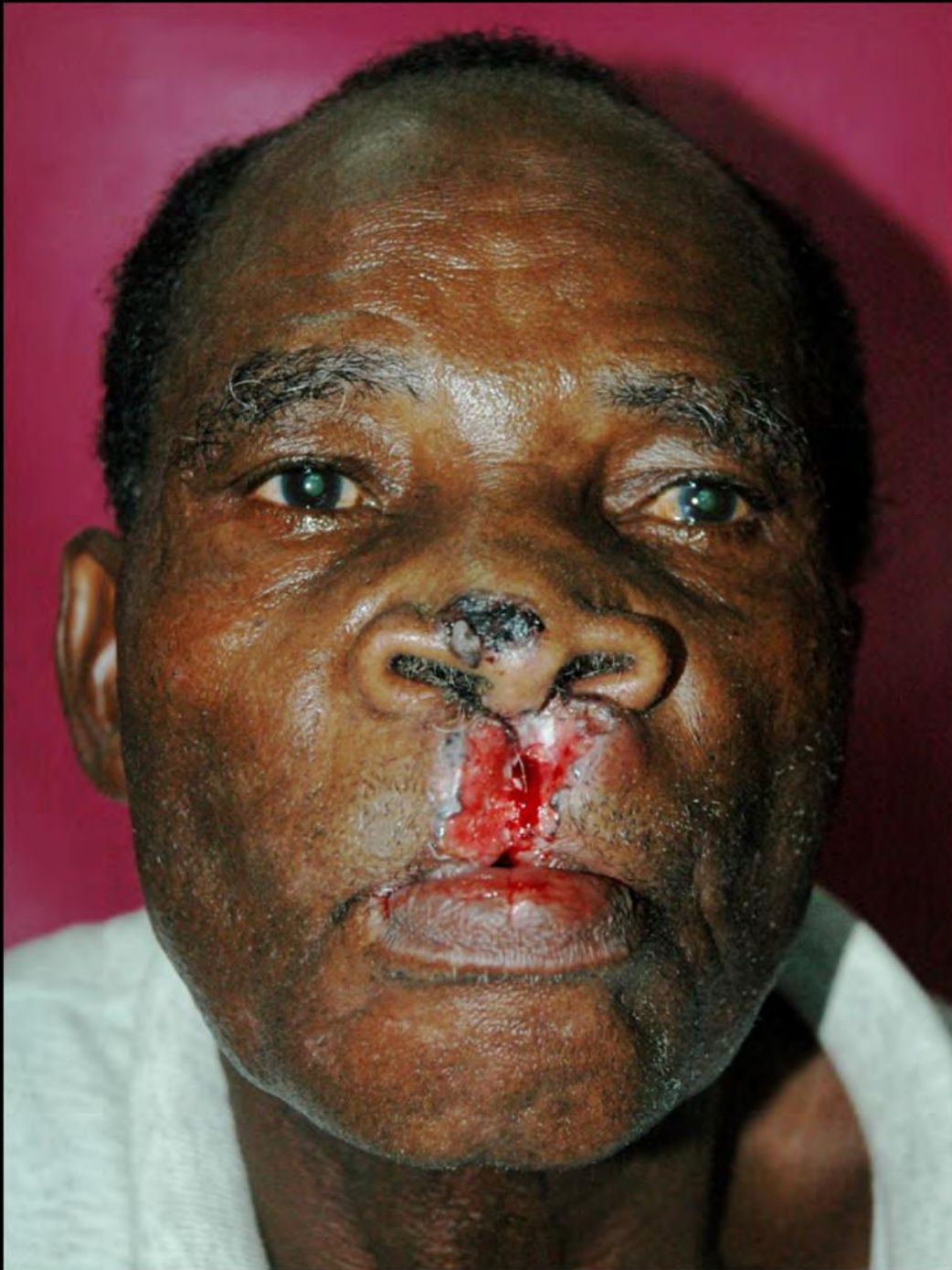
Joshua came into the operating room in November, 2010 with a Band-aid across his upper lip. I didn't realize that the Band-aid was practically holding his face together. He had a tumor of the lip that had been present for years. The tumor was previously removed but recurred. The tumor involved the entire upper lip and destroyed the central portion. There was a separate lesion on his nose.

The surgery required removal of the entire upper lip. After you remove someone's entire lip, you realize there's no going back! We then reconstructed the mouth with a Gillies type Fan Flap. We cauterized the lesion on his nose.

I was so happy when he came back to see me three months later. His mouth was smaller, of course, but he could open it wide and had good lip function. His speech was barely changed.

The tumor was a basal cell carcinoma. He refused radiation but has no recurrence to date.





“Without health life is not life; it is only a state of languor and suffering – an image of death.”

– Buddha

## Rita and Chinyere

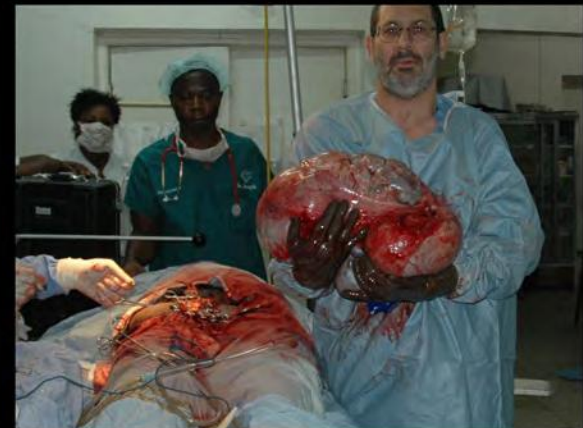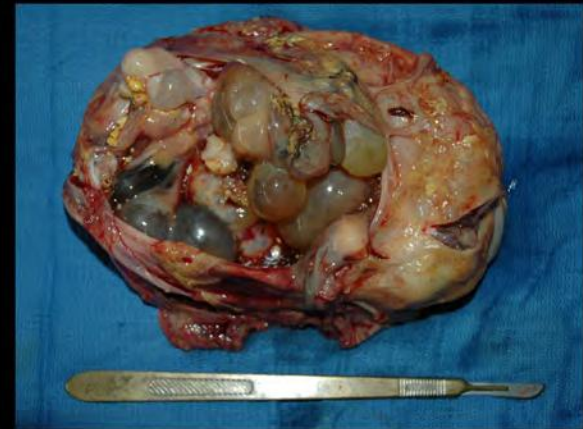
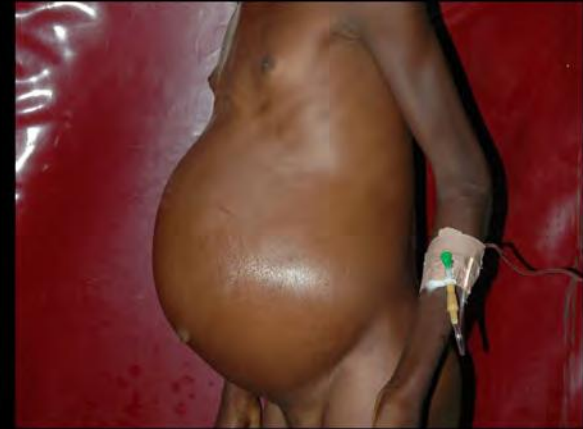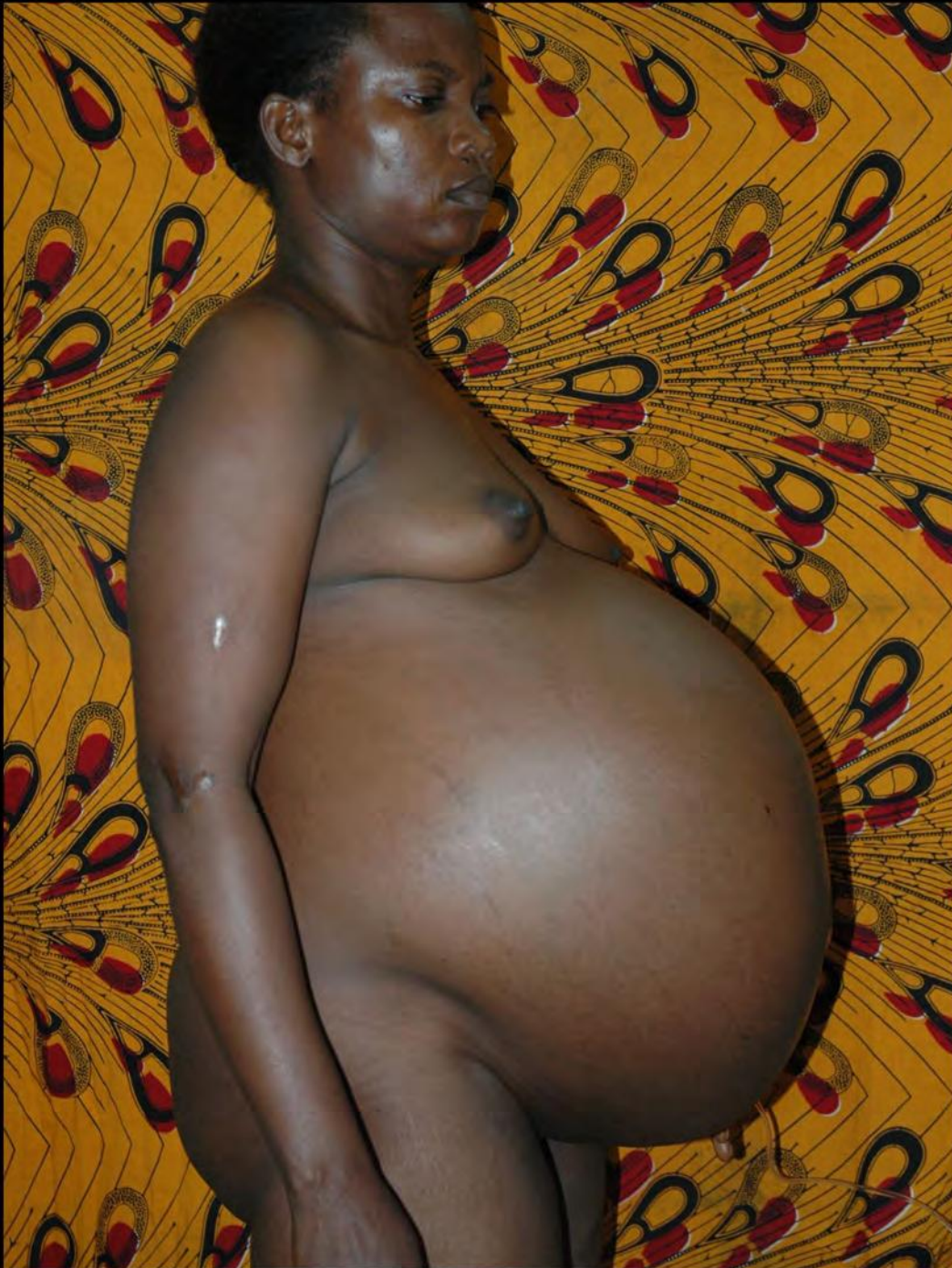---

I met both Rita (10 years-old) and Chinyere (32 years-old) in 2010. These two people had giant abdominal masses and were really uncomfortable. They couldn't eat and could barely move. Rita's tumor weighed more than 25 pounds!

Both patients had giant cystic teratomas of the ovary-germ cell tumors that are commonly composed of multiple cell types from one or more of the three germ layers. These tumors are usually not malignant and are usually very easy to remove. Recovery is usually very fast, as well.

After surgery, both patients felt like they were floating on air. It was great to make such a dramatic change in their lives.





“All existing things are really one. We regard those that are beautiful and rare as valuable, and those that are ugly as foul and rotten. The foul and rotten may come to be transformed into what is rare and valuable, and the rare and valuable into what is foul and rotten.”  
– Zhuangzi

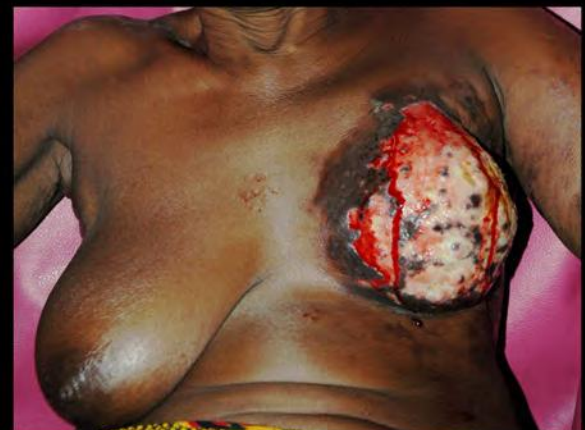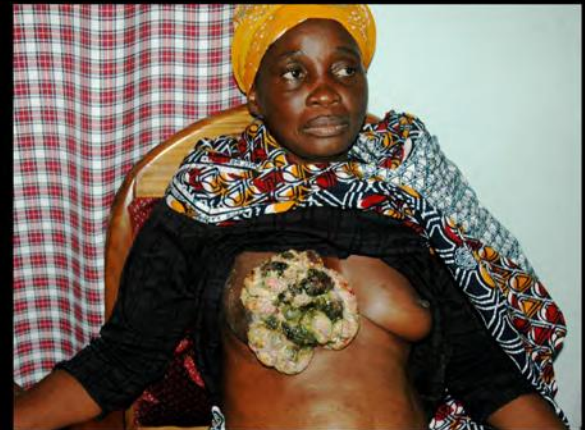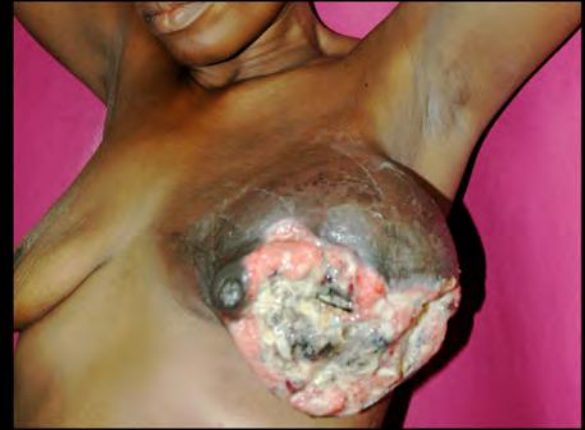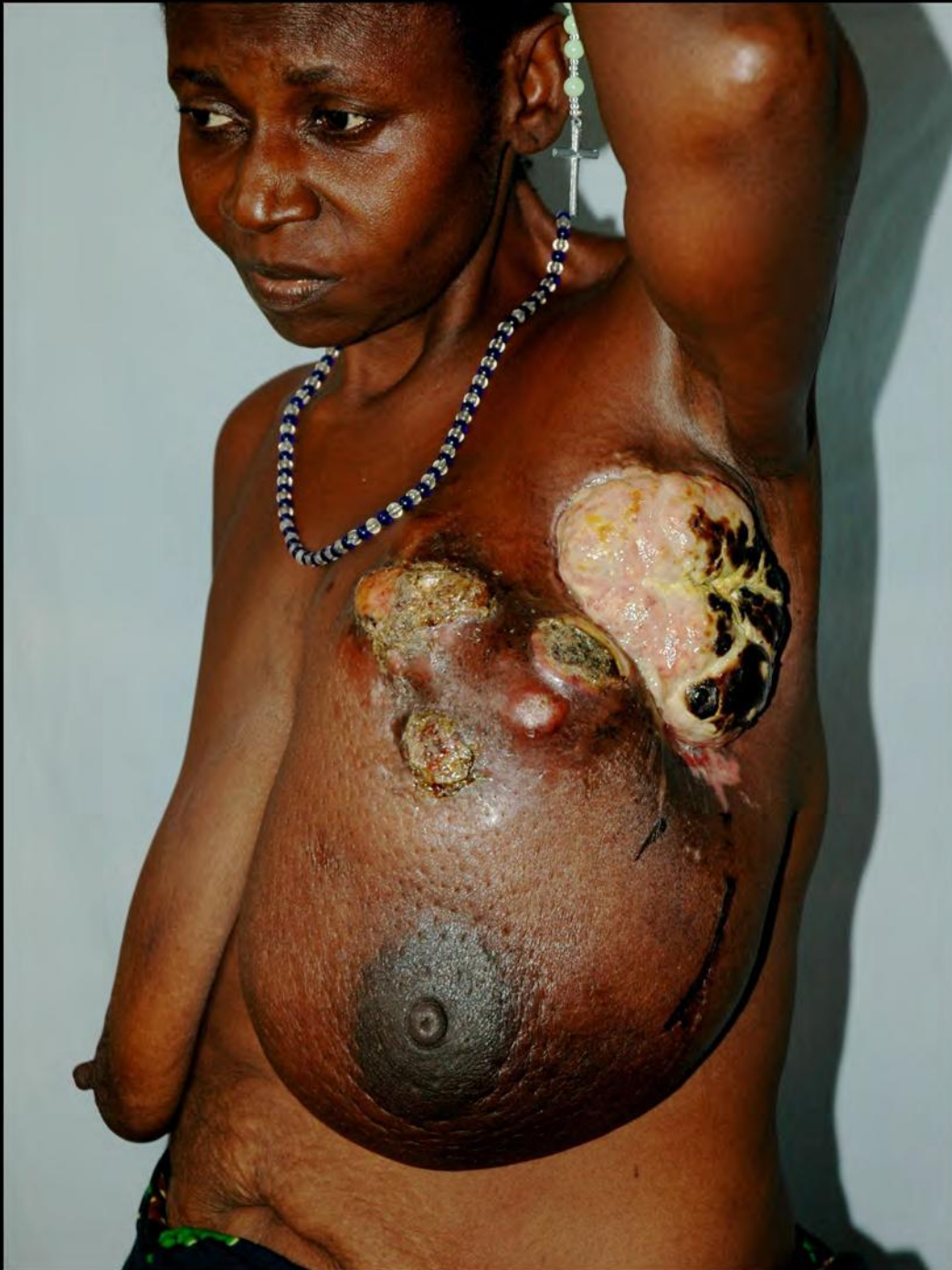
## Breasts

---

There is nothing worse than the smell of rotting flesh. Unfortunately, it is a smell that is often associated with breast cancer in Nigeria. Either through denial, lack of education, fear, or all of these-many Nigerian women (and occasionally men) present in the late stages of breast cancer. The tumor erodes through the skin and rots. Sometimes the patients come for consultation and ask for a pill to make it go away! Often there is nothing we can do. We try chemotherapy, radiation, and surgery but many succumb to the disease. For many, death is a release since they suffer so much with their disease.

All the women pictured battled their cancer-some won and some lost. They were all brave.





“Start on clavicle. Remove middle third. Control and divide subscart and vein. Divide large nerve trunks around these as prox as poses. Then come onto chest wall immed anterior and divide Pec maj origin from remaining clav. Divide pec minor insertion and (very imp) divide origin and get deep to serrates anterior. Your hand sweeps behind scapula. Divide all muscles attached to scapula. Stop muscle bleeding with count suture. Easy! Good luck. Meirion.” – (Text message to Dr. David Nott in the Congo from Dr. Meiron Thomas in the UK on how to perform a forequarter amputation on a boy whose arm was severed by a hippopotamus).

## Victoria

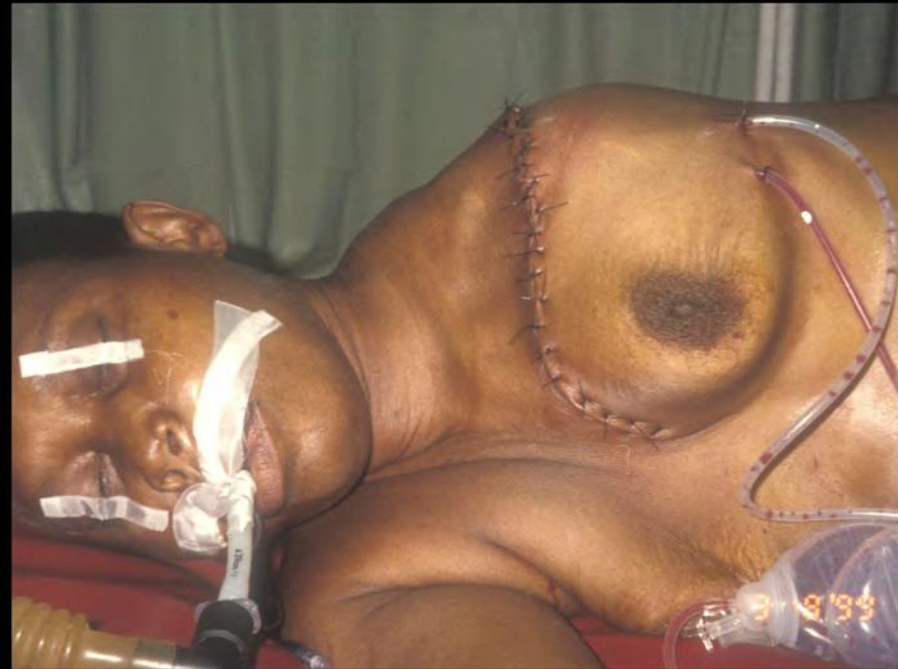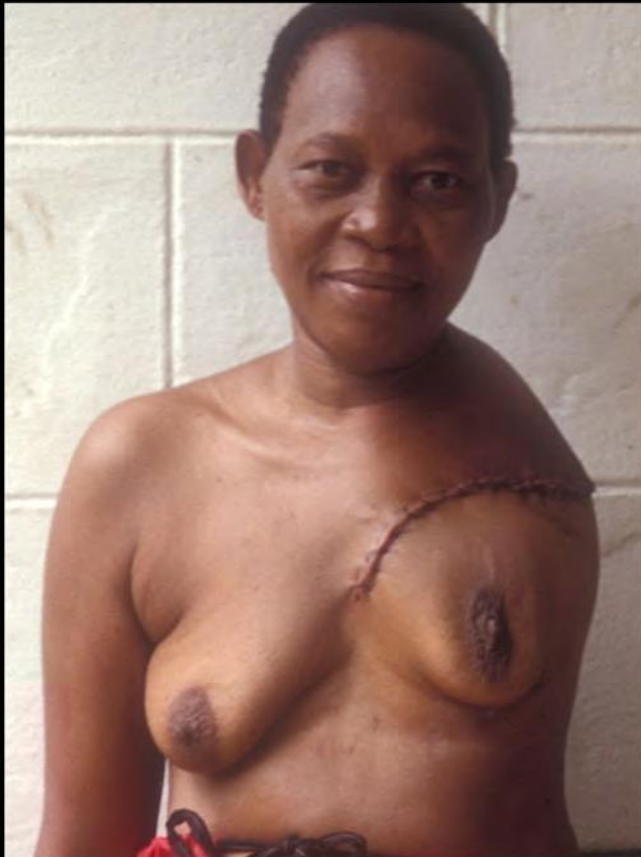
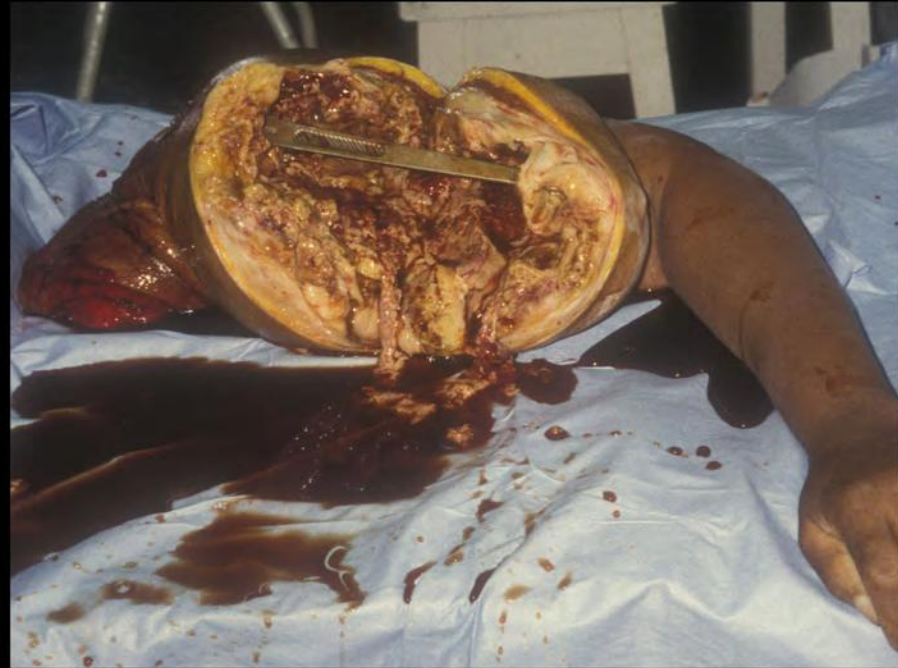
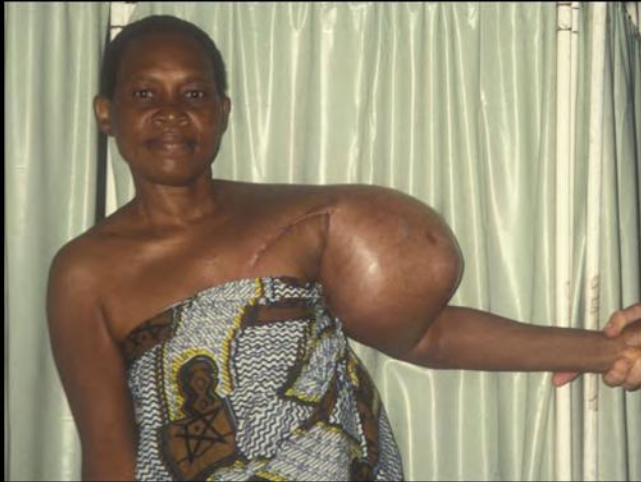
---

I met this sweet lady in 1999. Like many of my patients, she had a very large tumor and it had been operated on previously. The tumor was so big that she could not lift her arm. I offered her the only possible treatment-which was a forequarter amputation-amputation of the arm, clavicle and scapula. There were two problems with this recommendation. One, amputations are abhorrent to most Nigerians since prostheses are not readily available. Two, I had never done this operation. This lady wanted to live and she and her husband agreed to proceed.

I studied the anatomy and dreamed about the operation during the night. When I came in the next day, I was ready. We positioned the patient and the surgery began. And then it was over. In less than one hour we achieved our goal! I didn't remember doing the surgery-I was in the zone. Victoria had an uneventful recovery and was out of bed the next day. The tumor was a liposarcoma-a malignant sarcoma that arises from fat cells. She lived five more years until she died from metastatic disease. I have subsequently performed this surgery several times including February,

2011, when a young man's arm was irreversibly destroyed from an electrical burn.





## (Obioma) Blessing

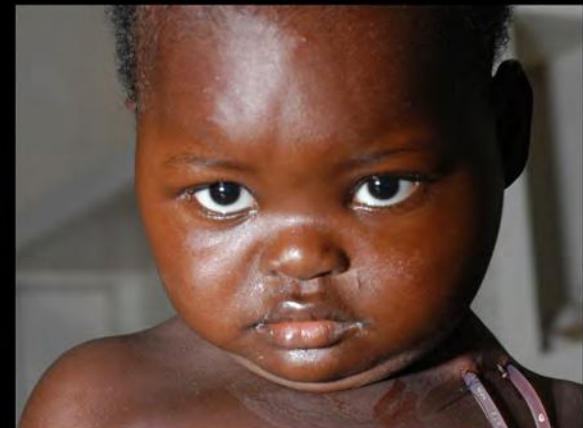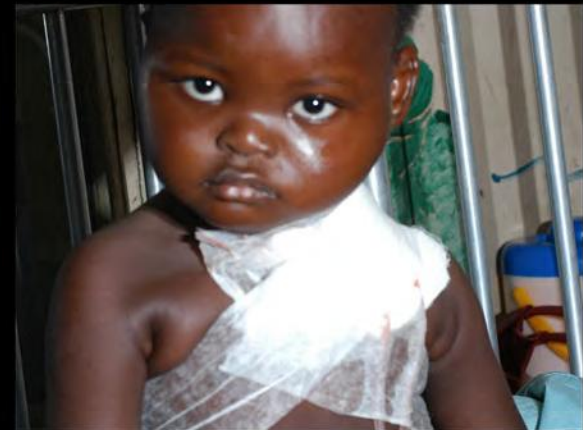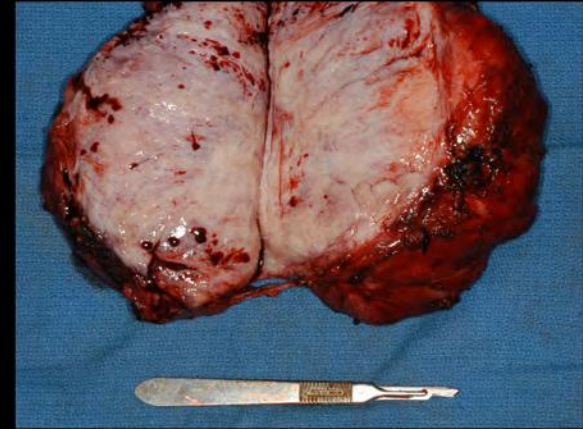
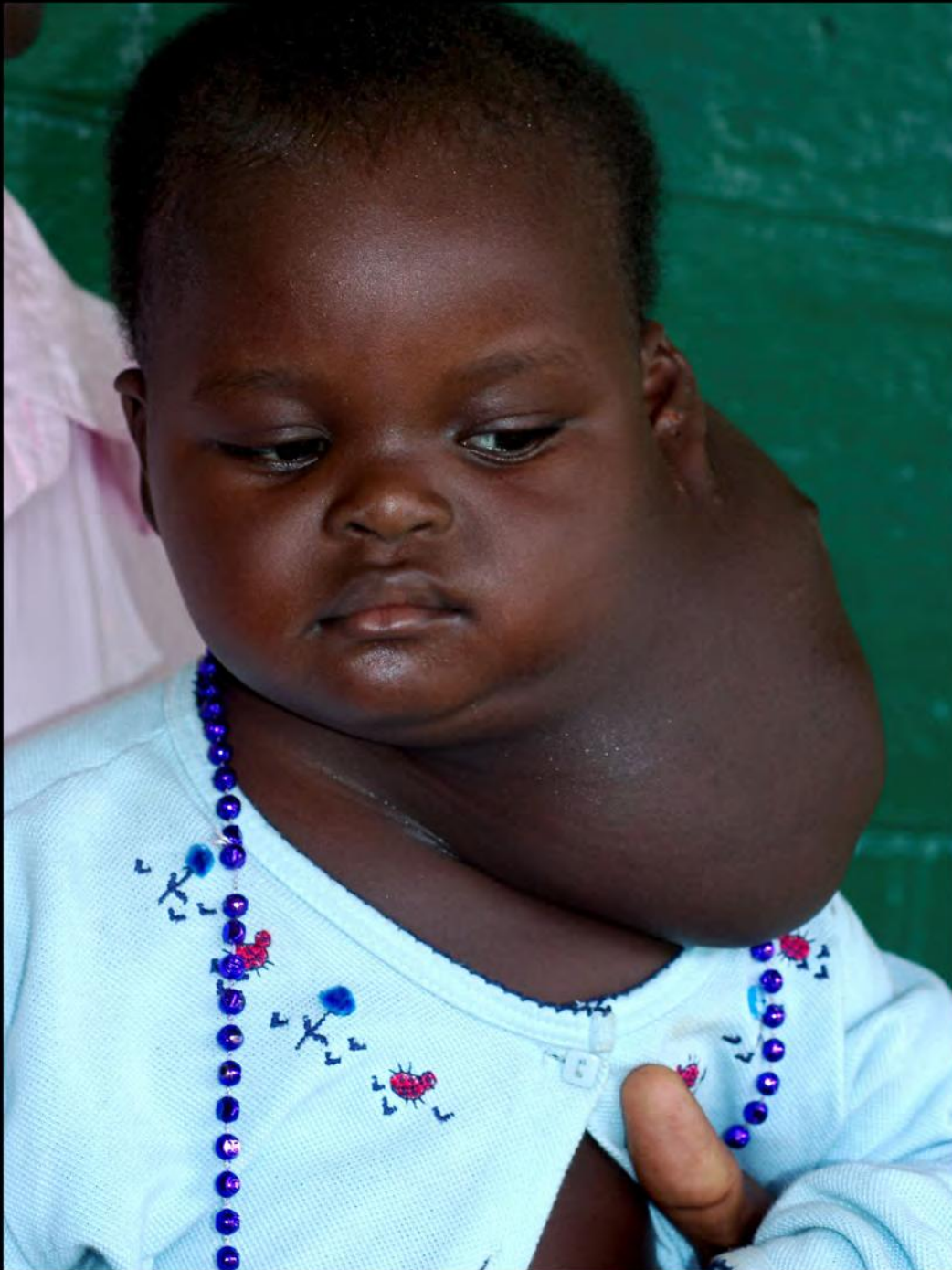---

This cute little girl came to NCH with her mother in 2004. She had a left neck mass that had been growing since birth.

We did a very careful surgery and removed the mass. Despite giving her a doll, she was never really happy to see us.

The tumor was a benign neural tumor and she made an uneventful recovery.





“Life is short, the art long, opportunity fleeting, experiment treacherous, judgment difficult.”

– Hippocrates

# Mercy

---

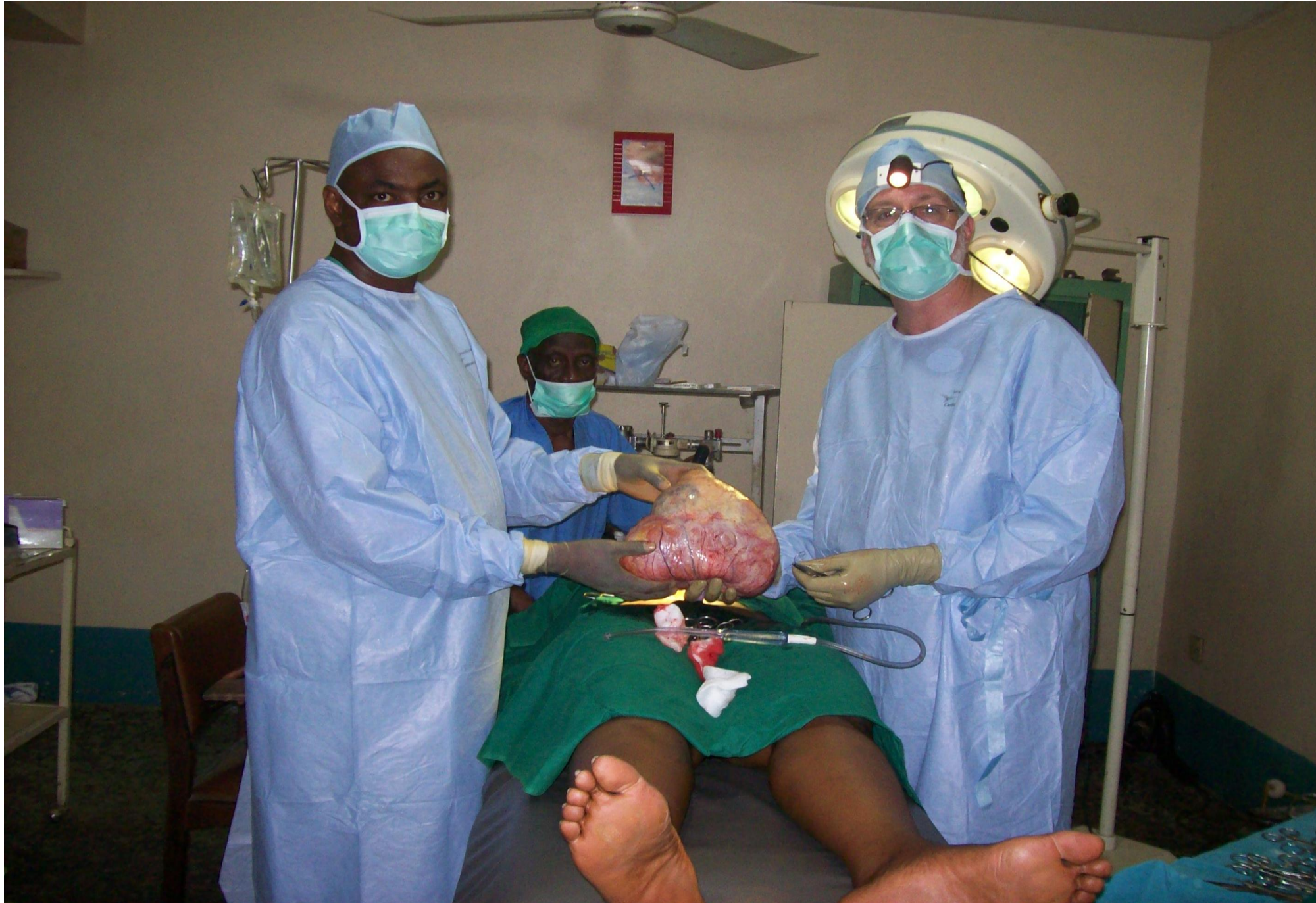Mercy arrived at NCH in 2002 but refused surgery. She came back in June, 2004, just as I arrived with my brother, Scott Camazine, MD. The tumor had grown and Mercy agreed to surgery.

Mercy had a large maxillary tumor. Dr. Farrar had showed me how to do these surgeries, but he wasn't there to hold my hand. I cracked open the “Bible”, Lore's Atlas of Head and Neck Surgery, and studied my lessons. The next day my brother and I proceeded with surgery.

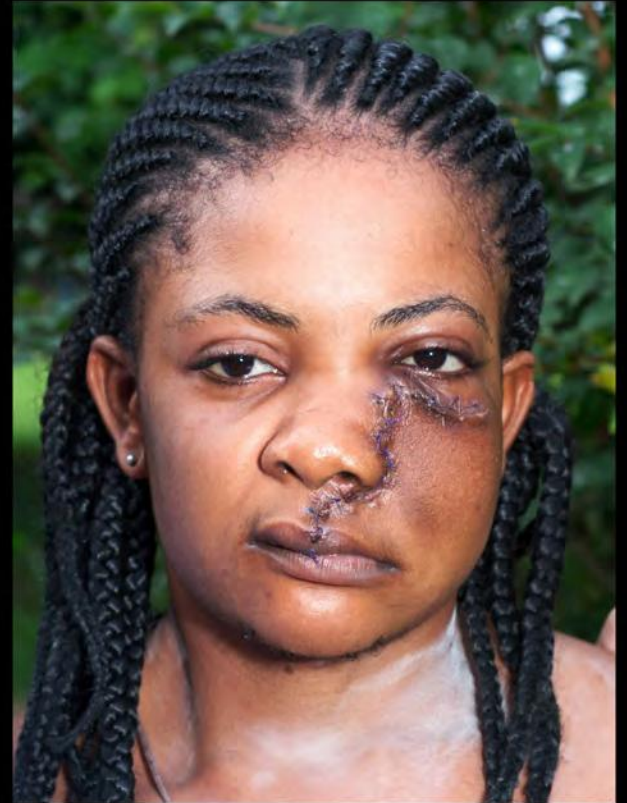
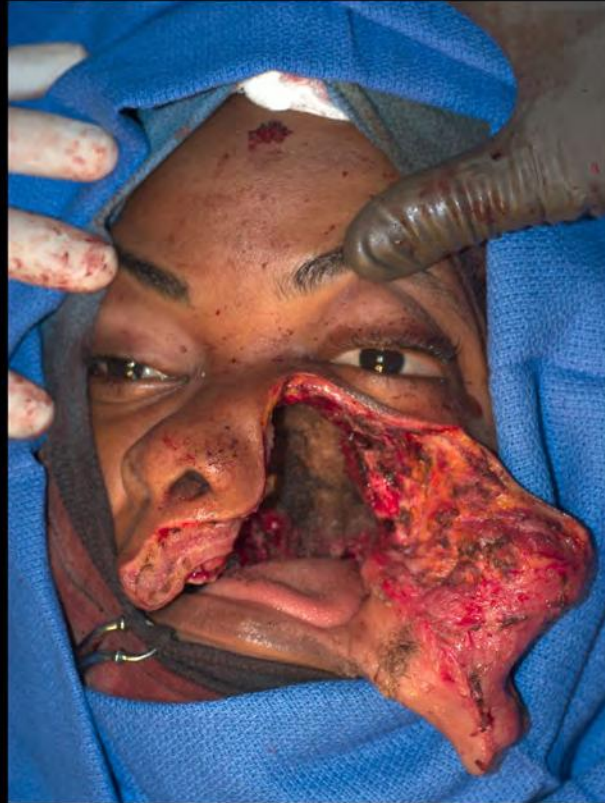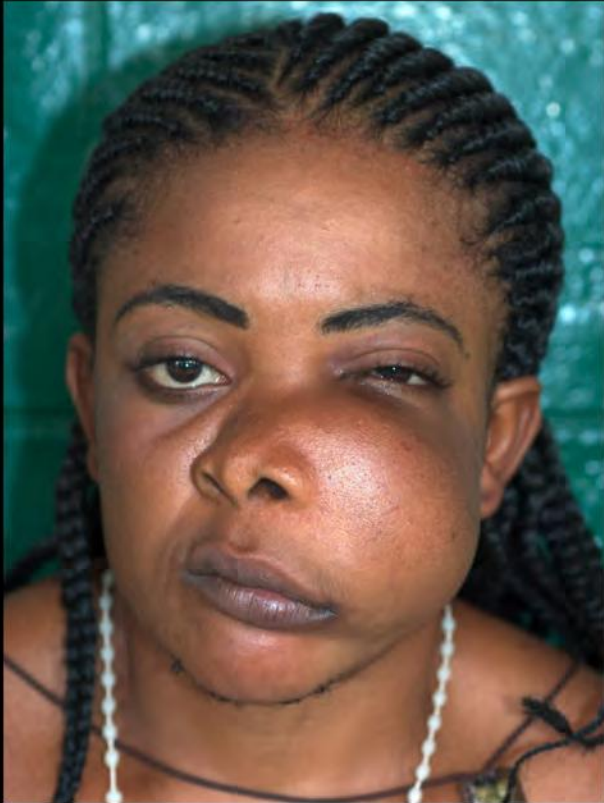We girded our loins, opened Mercy's face and removed the tumor. It was quite daunting when the face was open. We appeared to be gazing into a deadly abyss. We plodded on and reconstructed her face. The surgery turned out great and she made a rapid recovery.

The pathology showed a benign giant cell tumor-a tumor of undifferentiated mesenchymal cells of the bone marrow.











“And in the end it’s not the years in your life that count. It’s the life in your years.”

– Abraham Lincoln

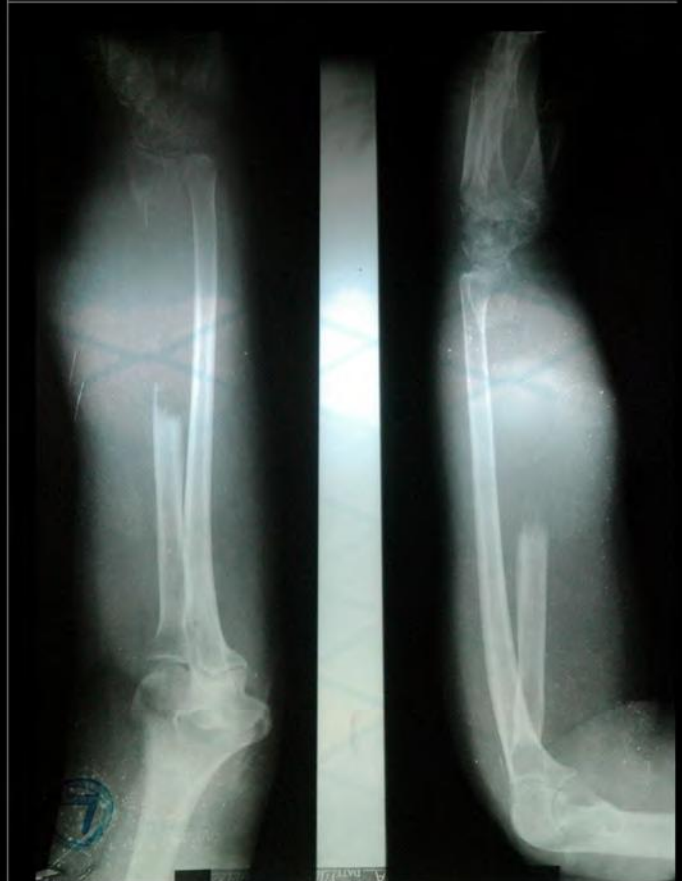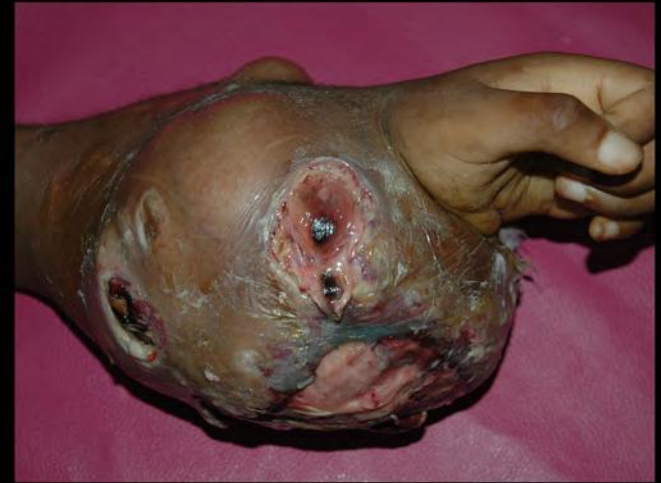## Chinwendu

---

When twenty-five year-old Chinwendu arrived in April, 2010, it was obvious, from a single look, that she was a delightful woman-but one with a big problem. She had a tumor of the wrist that had destroyed her hand. Her ulnar bone was gone. The tumor was obviously a sarcoma of some type and amputation was the only treatment. Unfortunately, it would not be a cure.

We proceeded with amputation and she recovered rapidly. She came back to see me in July, 2010 and was happy and looking well. In December, however, she developed a small metastasis on her leg that we removed. Several more appeared over the next six months and we started her on chemotherapy. Overall, her prognosis is poor. Despite this, she remains upbeat.

The pathology showed rhabdomyosarcoma-a sarcoma in which the cancer cells arise from skeletal muscles.





“The two most powerful warriors are patience and time.” – Leo Tolstoy

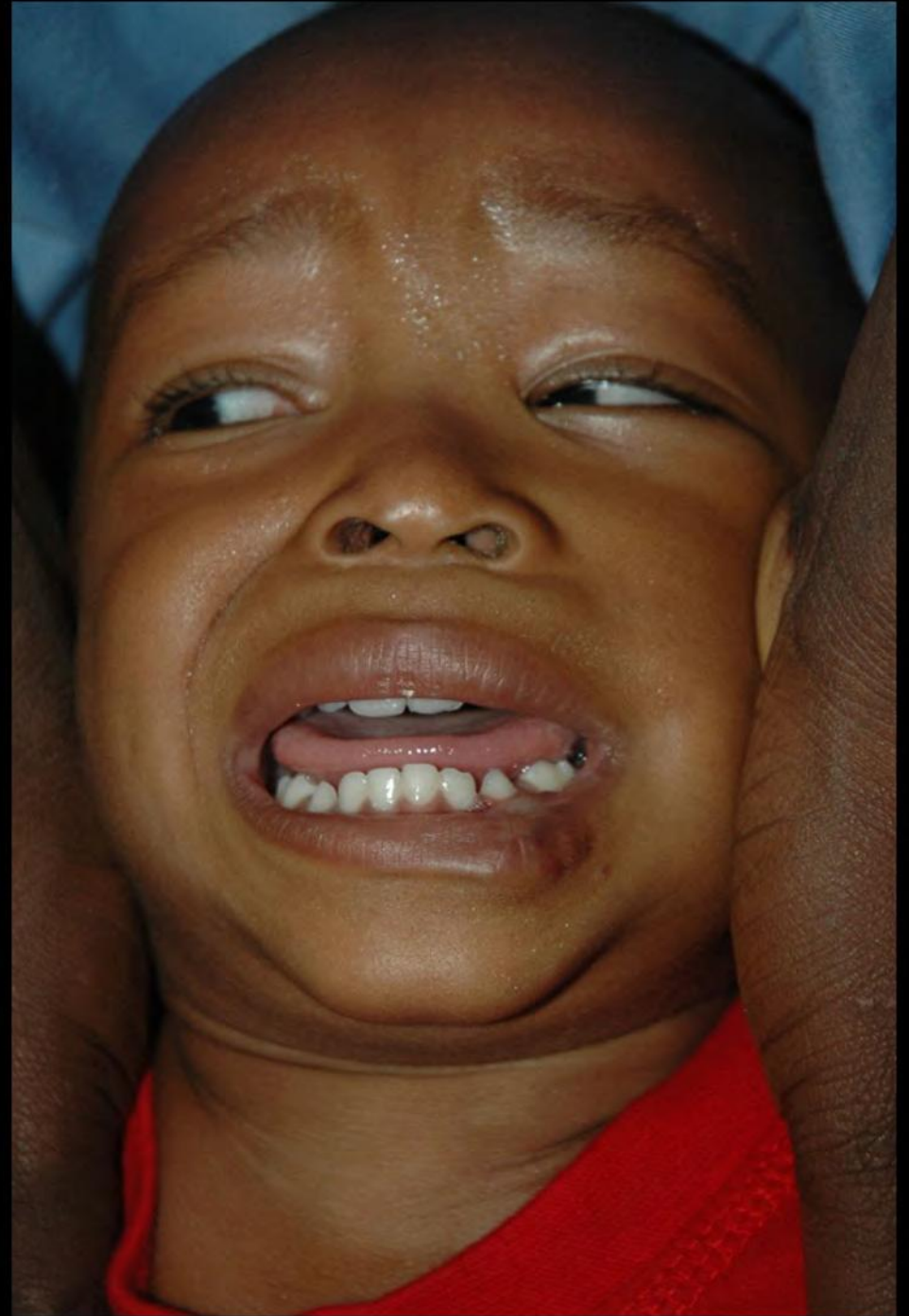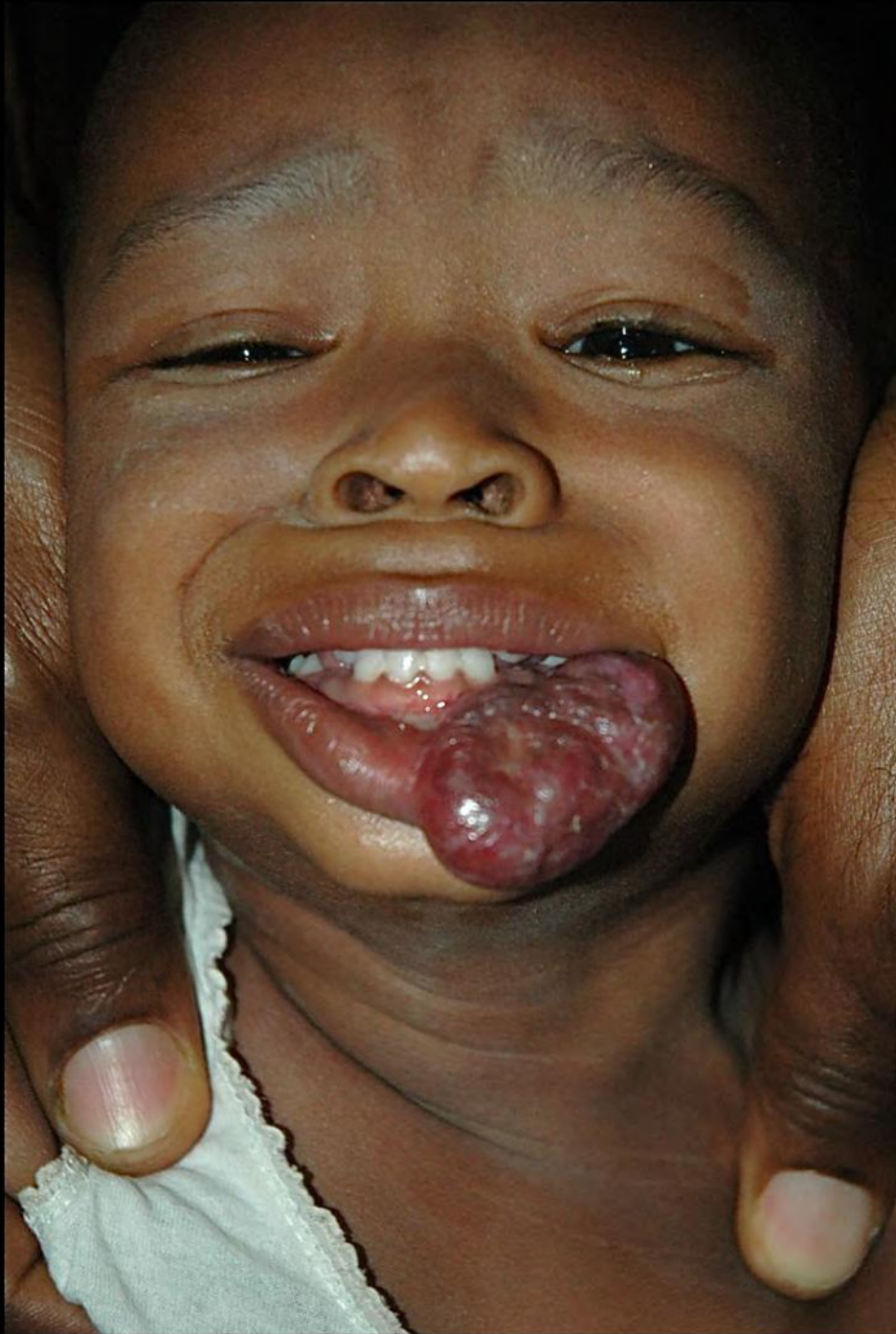## Sepuruchi

---

Sepuruchi was a wild banshee from the moment I saw her February, 2011. She didn't want to have anything to do with examinations, surgery or me. She had a benign hemangioma of the lip (a collection of blood vessels) that was growing.

At first, I considered doing some very fancy surgery such as an Abbe-Estlander Lip switch in which a portion of the upper lip is transferred to the lower lip. But then I remembered KISS (Keep It Simple Stupid). I decided to just excise the lesion, and, if the results were unsatisfactory, return for a more complicated surgery.

I did the operation and, in the week following surgery, it looked worse every day!. I fretted about it day and night. Finally, I told the Mom we would see how it looked on the next trip. When she returned July, 2011, my dreams were fulfilled. The result wasn't perfect but it was pretty good and Mom was happy. Sepuruchi still wasn't, however.





“In reality, serendipity accounts for one percent of the blessings we receive in life, work and love. The other 99 percent is due to our efforts.”  
– Peter McWilliams

## Uche

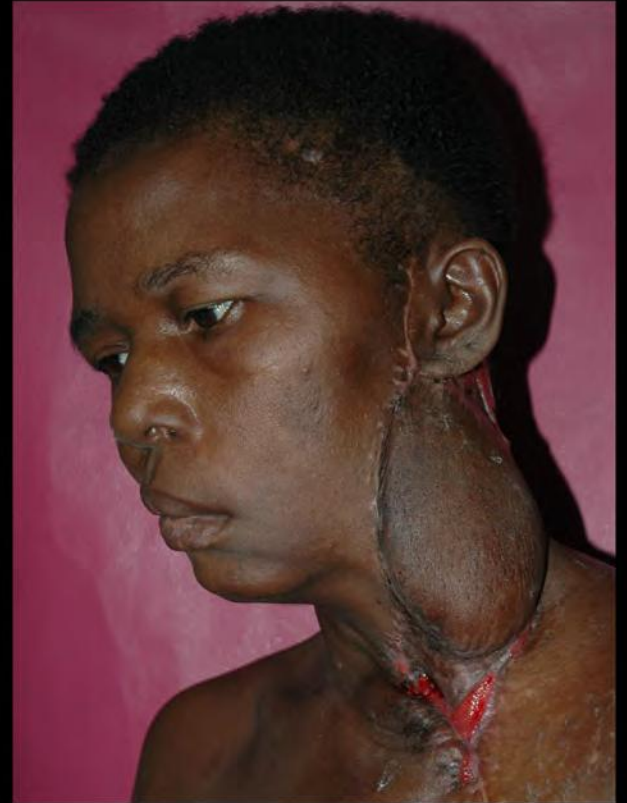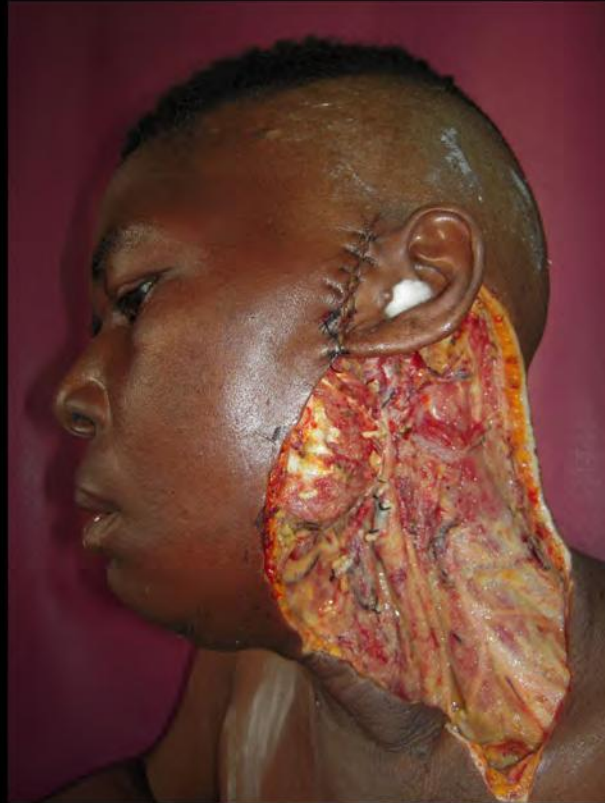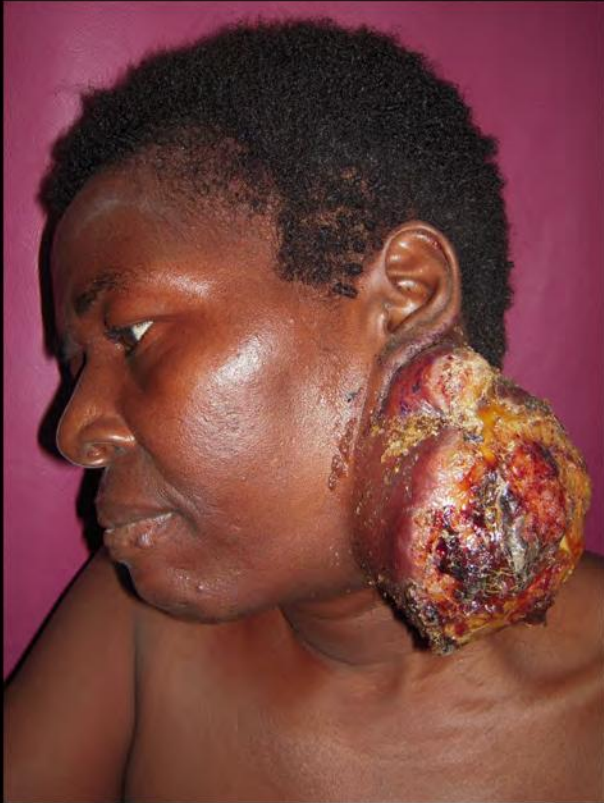---

Uche arrived at NCH in January, 2010. She had a recurrent fungating mass below her left ear. Once again, I called my friend, Dr. Mike Enyinnah for assistance.

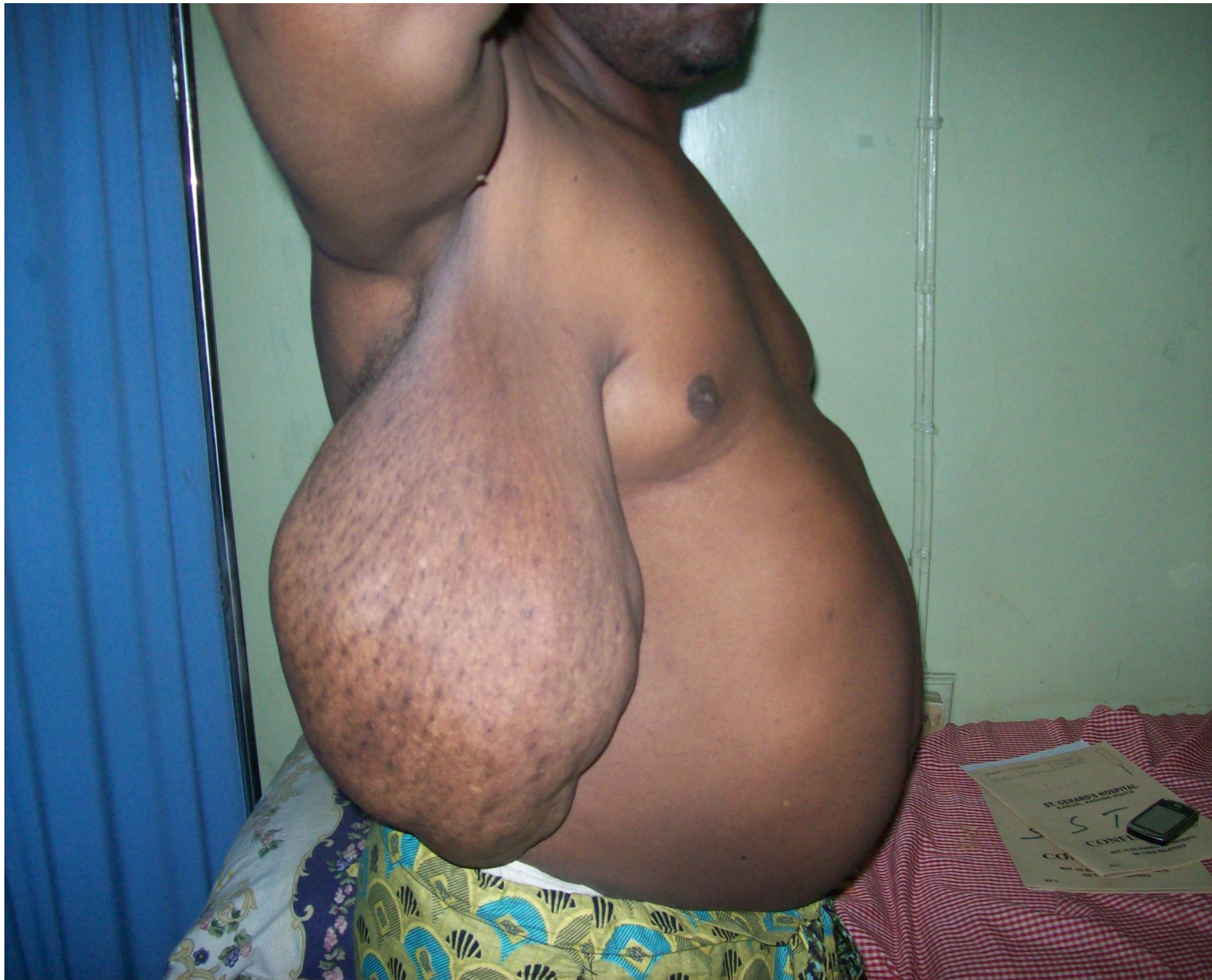We removed the tumor but the surgery left a large defect of skin. After the patient recovered for a few days, we took her back to surgery and performed a pectoralis major muscle flap to close the wound.

After the second surgery, she asked me to call her brother in the USA. Amazingly, he lives only four hours from my house. When I returned to the USA, he came to visit me and we have become great friends!

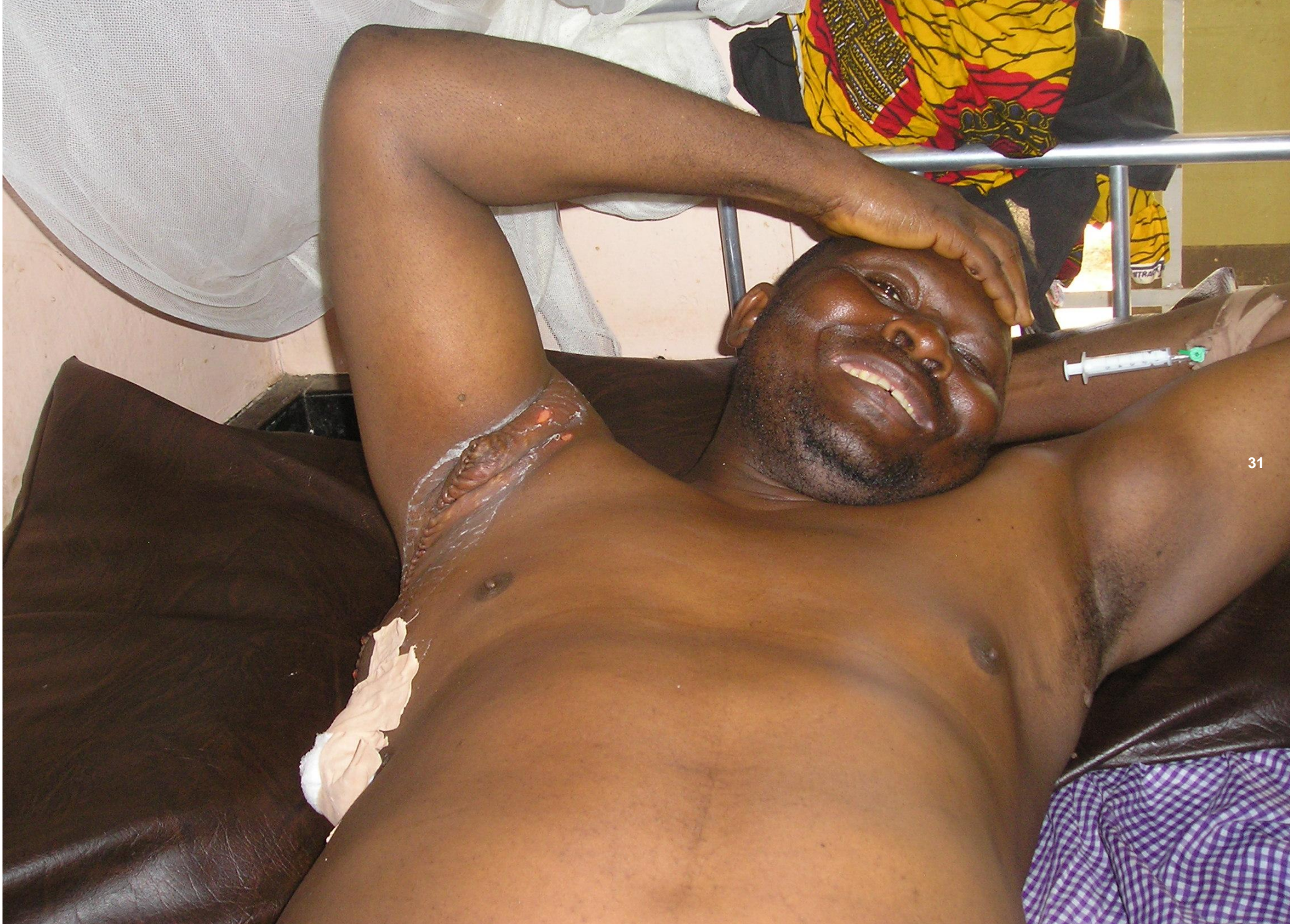The pathology, not surprisingly, showed mucoepidermoid carcinoma—a cancer of the salivary glands (in this case the parotid gland) that is very resistant to chemotherapy and radiation. Nonetheless, we sent her for radiation. Unfortunately, she died July, 2011.



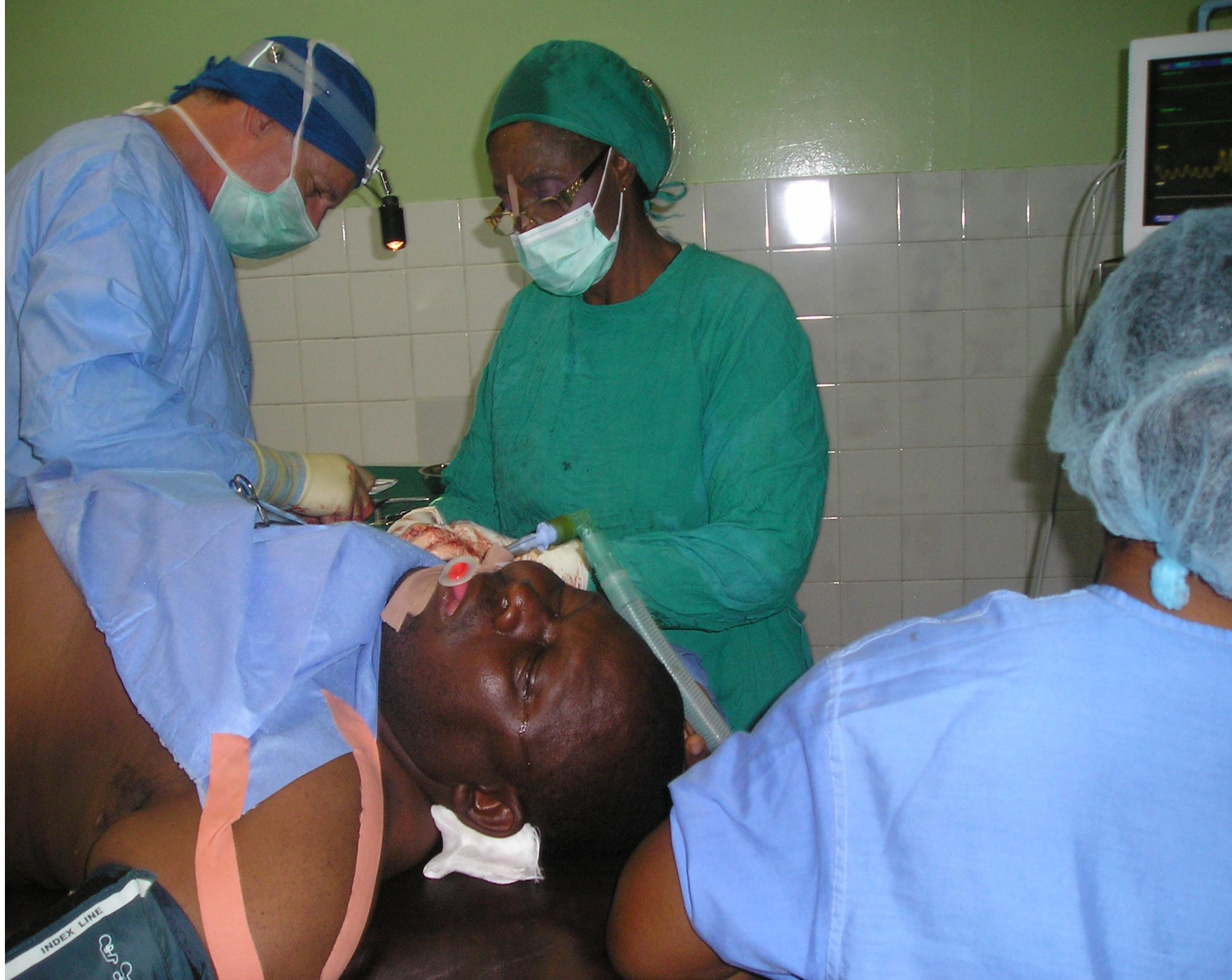




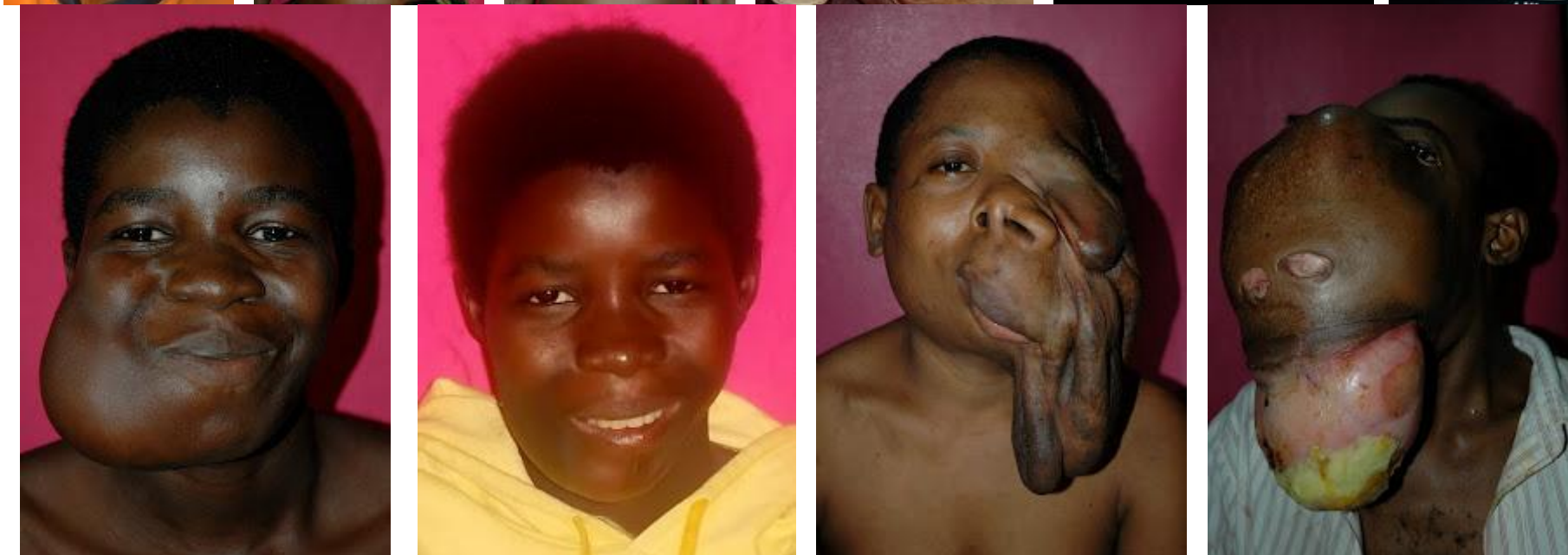
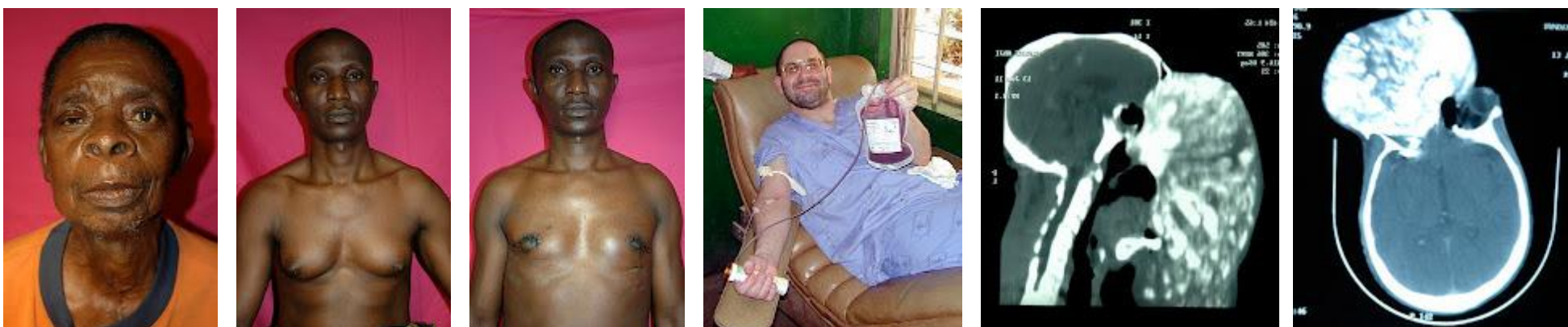











# ugechi

***“Nobody will read what I say here, no one will come to help me; even if all the people were commanded to help me, every door and window would remain shut, everybody would take to bed and draw the bed-clothes over his head, the whole earth would become an inn for the night. And there is sense in that, for nobody knows of me, and if anyone knew he would not know where I could be found, and if he knew where I could be found, he would not know how to deal with me, he would not know how to help me. The thought of helping me is an illness that has to be cured by taking to one’s bed.”***

– Franz Kafka, *The Hunter Gracchus*

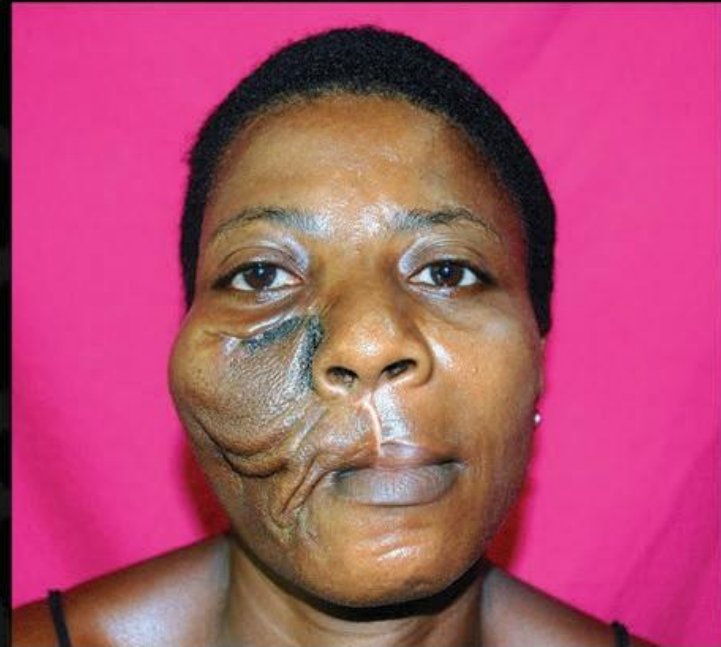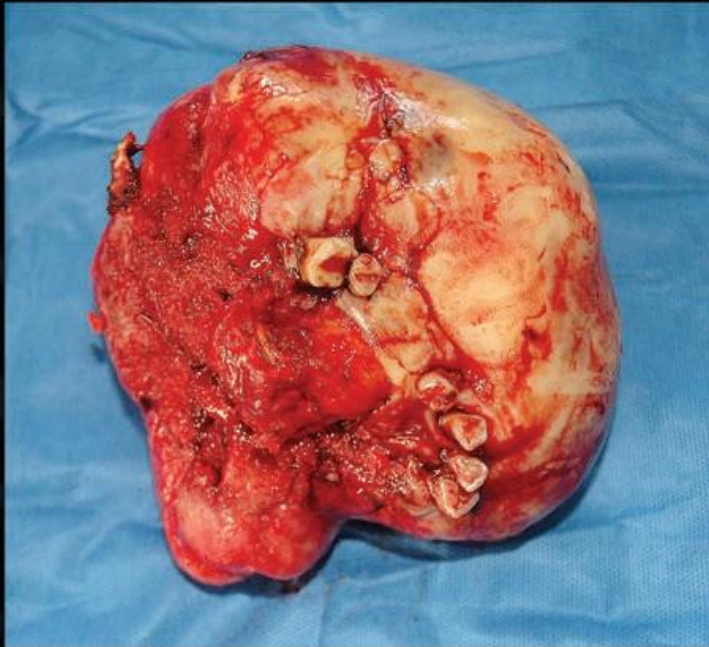
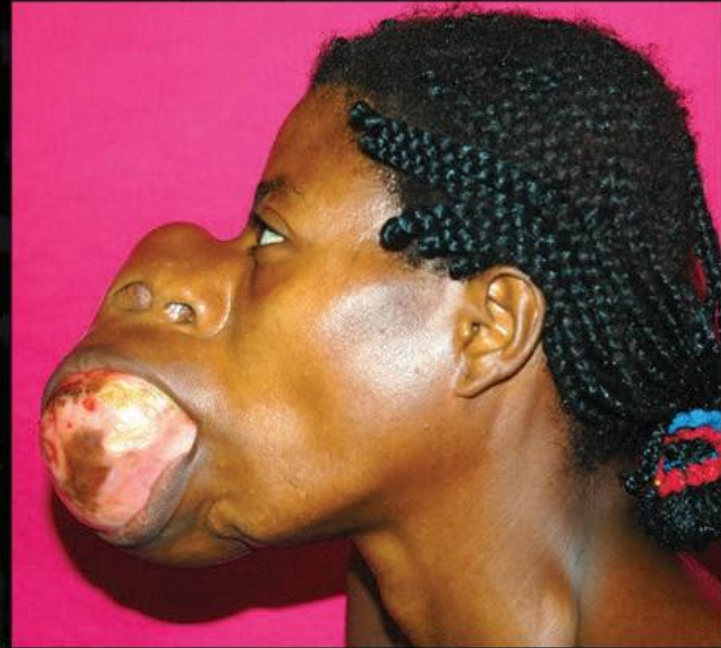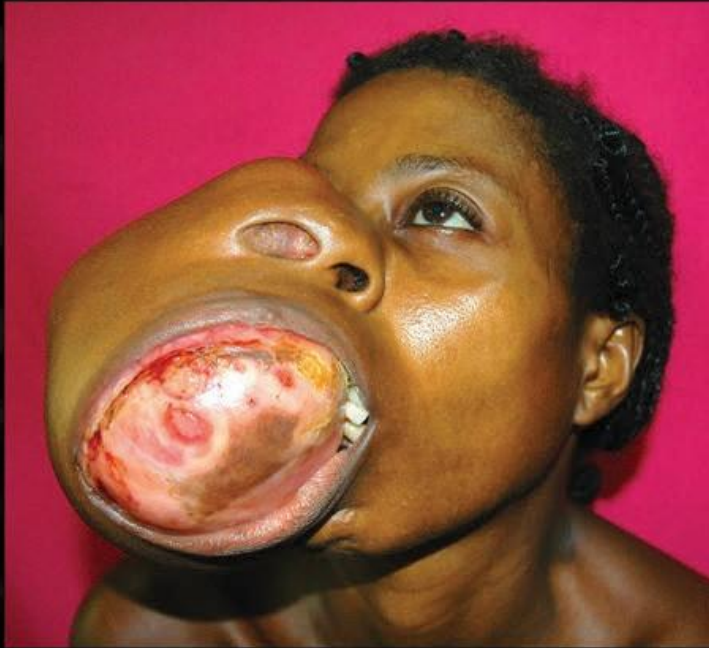Ugechi came to see us January 2013. She was subdued and timid from years of being shunned in her village. She had a scarf covering her face. I removed the scarf and told her she did not need it at the hospital and would not need it anymore. We would help her.

Ugechi had a massive tumor of the maxilla that made it difficult to breath and eat. We started the surgery by performing a tracheostomy. Next, we resected the tumor. The tumor was so large it had stretched her facial skin. This would be a problem for another surgery and another day. The tumor had destroyed her orbital floor; this we reconstructed with a vicryl mesh sling in order to prevent her eyeball from dropping into her maxillary sinus.

Ugechi made a great recovery. I saw her 6 months later, and she looked great and was very happy with the results. She was not wearing her scarf. I wanted to do another surgery to address the redundant skin on her cheek, but she refused. She was happy with the result.

The pathology showed fibrous dysplasia, a benign tumor where normal bone is replaced by fibrous tissue. It had not been so benign for her.







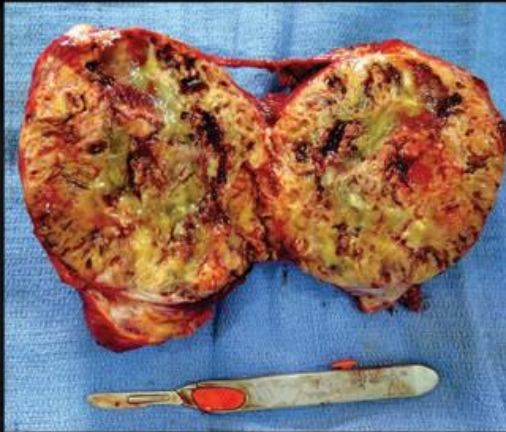
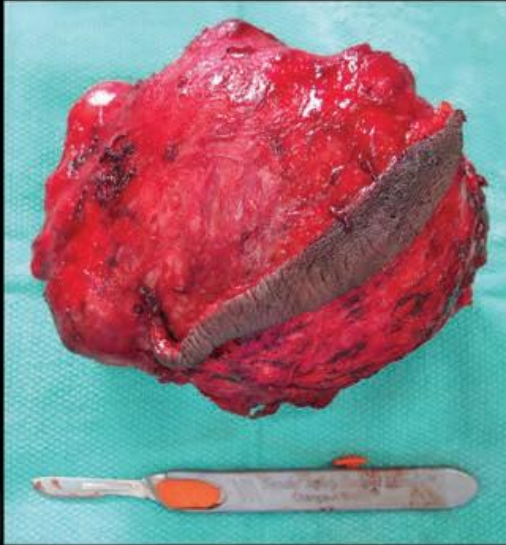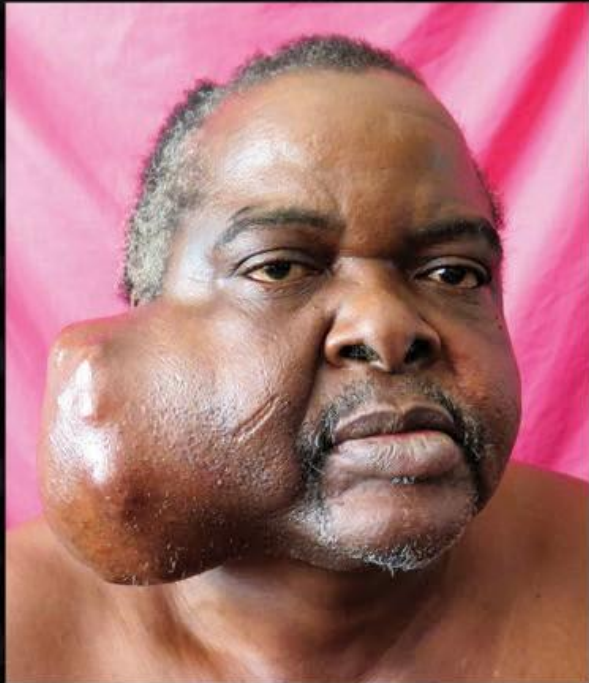# Okonkwo

***"He looks like a chipmunk with only one cheek pouch."*** – Brian Camazine, MD

Okonkwo had a parotid tumor that had been growing for more than a decade. He had had surgery once before, but the tumor soon grew back. We admitted him for resection towards the end of the January 2015 trip. He was a very pleasant man and patiently waited for his turn at surgery, which was quite some time since the hospital was full.

Complete resection required a radical parotidectomy; thus the facial nerve was divided causing a facial palsy. The surgery went very smoothly, and Okonkwo made a rapid recovery. He is happy with the results. The pathology showed pleomorphic adenoma with atypical features-thus it is probably benign.

The pathology showed pleomorphic adenoma with atypical features-thus it is probably benign. Pleomorphic adenoma is a common benign salivary gland neoplasm characterised by neoplastic proliferation of parenchymatous glandular cells along with myoepithelial components. It is the most common type of salivary gland tumor.





amos

***"I was recognizably human; I had at least the usual complement of legs and arms. But I might as well have been some shameful piece of garbage. There was something indecent about the way in which I was being furtively shuffled out of life."*** – Peter Greaves, leprosy patient

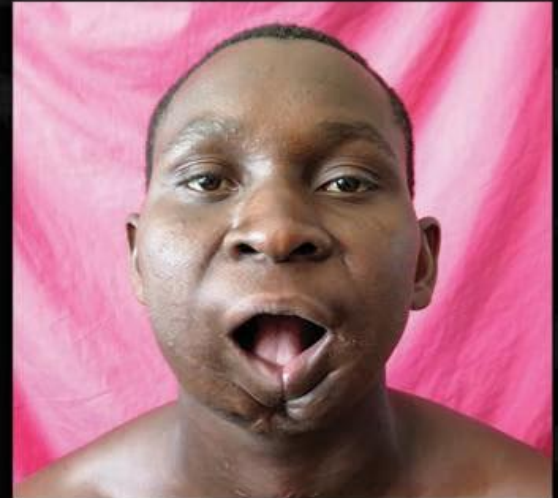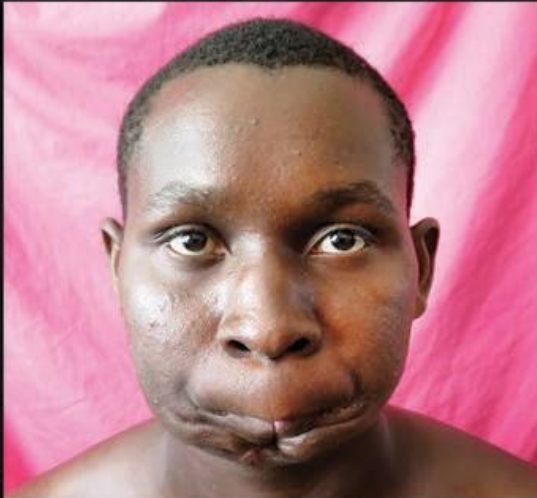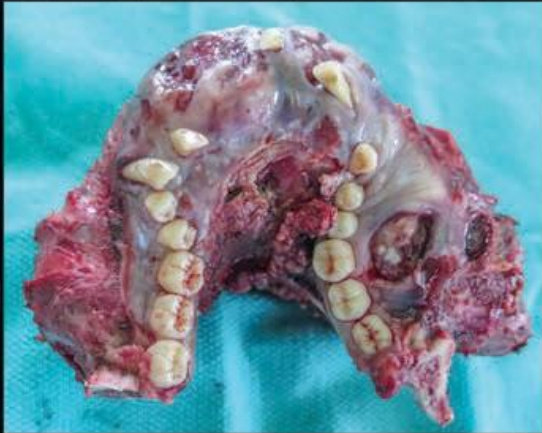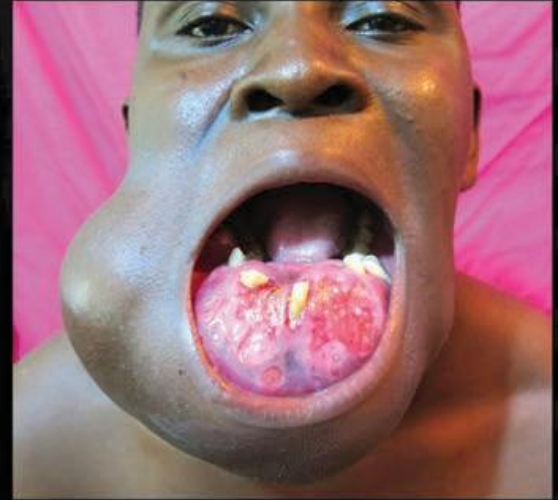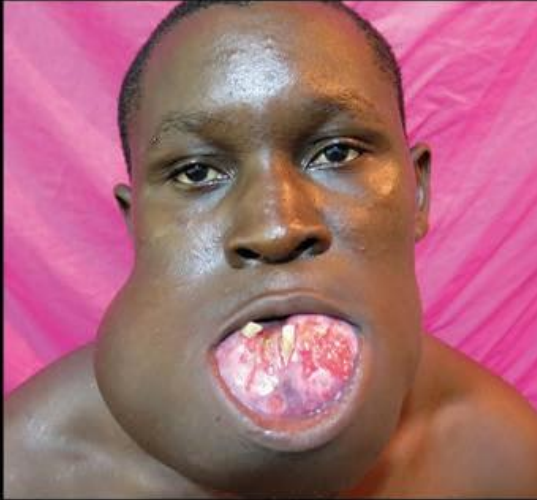Amos came to NCH in November, 2014. When he walked into the operating room, he had a mask over his face. I thought we were in big trouble; either the Boko Harum had arrived, or it was a stickup.

He was a very pleasant chap but somewhat subdued by his physical deformity. He had an obvious giant ameloblastoma that involved the entire lower mandible. Ameloblastoma (from the early English word amel, meaning enamel...the Greek word blastos, meaning germ) is a benign tumor of odontogenic epithelium.

Amos would need a total mandibulectomy to remove his tumor. Patients undergoing these surgeries can have trouble breathing as the tongue no longer has its attachments to the mandible that keep it from falling backward. In addition, they can have trouble eating and speaking after surgery.

The surgery went very well, and Amos had no problems. I saw him in January, 2015, and he had a big smile on his face. He was speaking almost normally and eating well. He was still able to eat the Nigerian staple, garri, which is a dough made from cassava tubers. It is usually dipped in a soup and swallowed without chewing. This is perfect for a person without a mandible.

Amos was very happy with his cosmetic results and his village no longer treats him as a pariah.





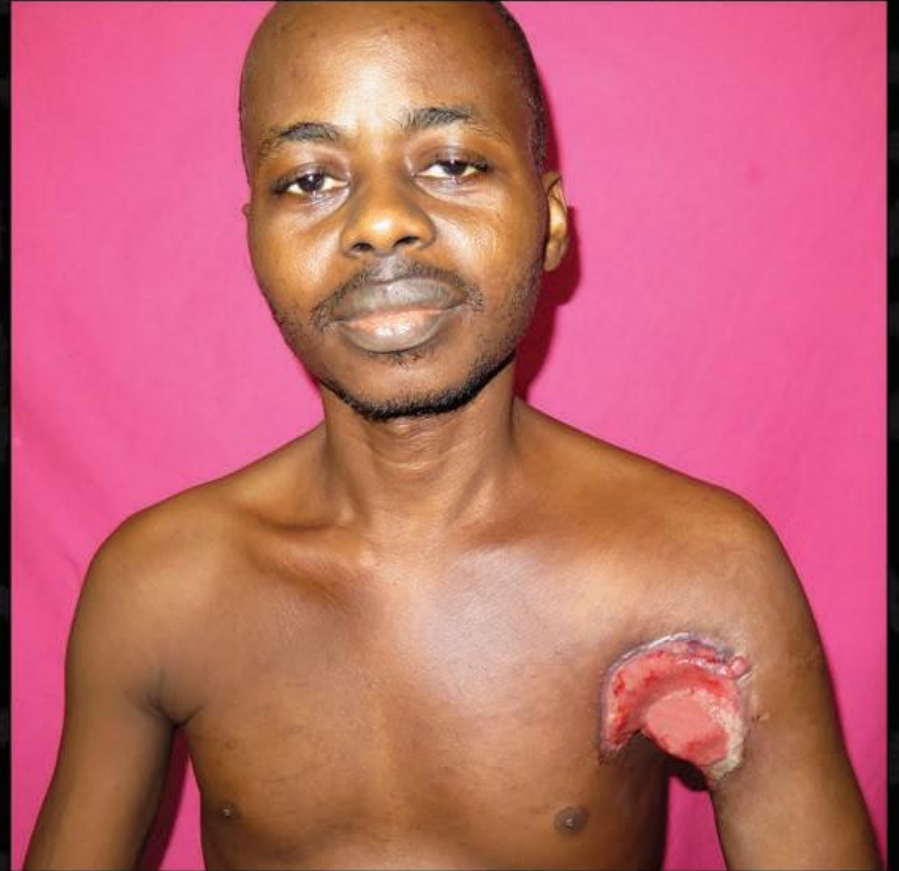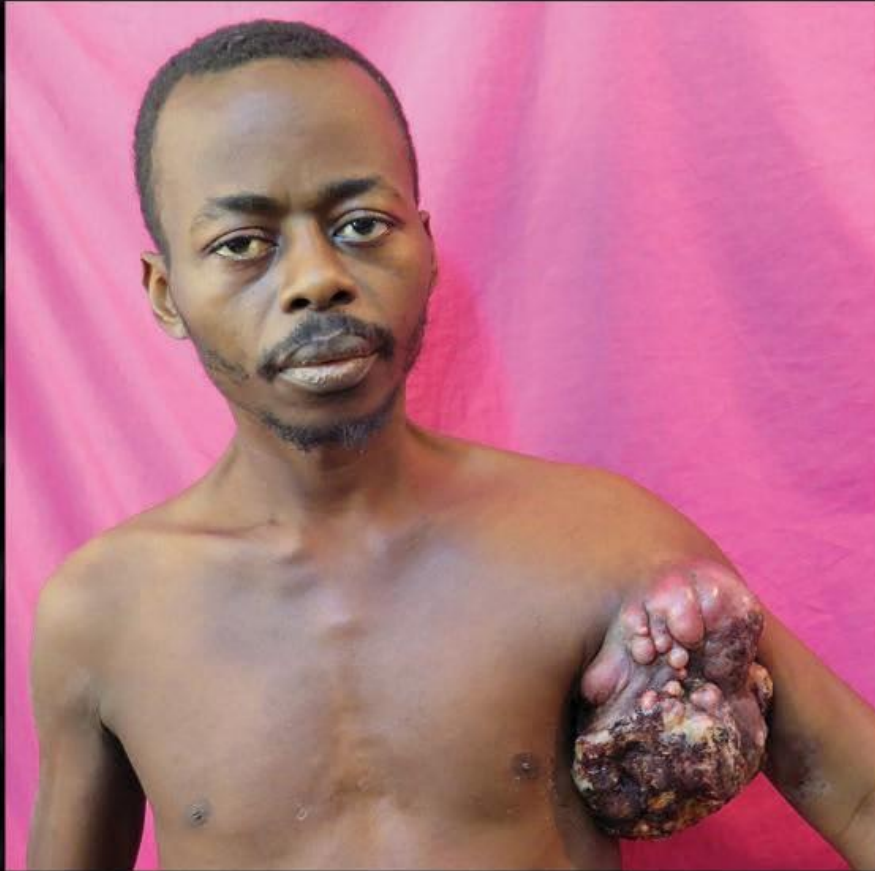*lucky*

***"It seemed like a silly name for someone so weak and smelly. Yet, in the end, who knows?"*** – Brian Camazine, MD

Lucky's brothers carried him into the consulting room in January 2015. He was pale and weak, and a terrible odor enveloped him. There was a huge mass in his left axilla that was covered with dirty bandages. I knew we were in for a shock. When I peeled off the dressings, blood started pumping out of the smelly, rotting tumor growing from his armpit. I quickly compressed the wound and redressed it.

Lucky's hematocrit was nine, so he only had about one-fourth the amount of red-blood cells that was normal, making him severely anemic. After transfusion, we brought him to the operating room for resection. Our main concern was that the mass might involve the axillary artery and vein or the brachial plexus. We planned to do the surgery slowly, with as little bleeding as possible, so that all of the critical structures could be identified and saved, if possible. Four of us scrubbed on the case. The tumor had huge feeding vessels, and everything we touched bled. Soon it was a race to get the tumor removed before too much blood was lost. So much for our battle plan. Six hands compressed bleeding vessels as I plowed through the surgery. Finally, identifying the axillary artery, vein and brachial plexus, we were able to remove the tumor rapidly. After 30 minutes, the tumor was off. All the critical structures were intact, and the bleeding stopped.

Lucky was weak and nutritionally depleted so we planned to do skin grafts the following trip. Following the surgery, Lucky started to gain weight and was happy to get rid of his hideous tumor. The pathology showed an apocrine hidradenocarcinoma, a malignant tumor of the sweat glands, that has a bad prognosis. He will receive chemotherapy and radiation therapy.





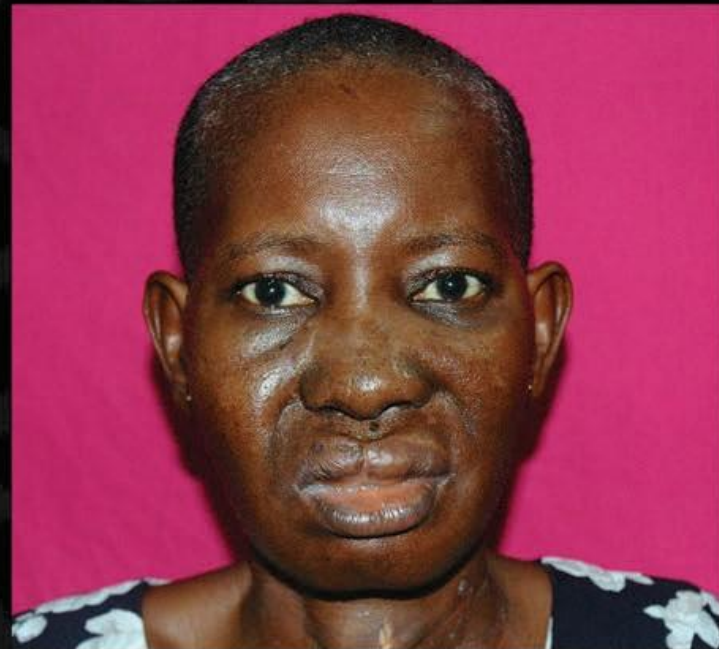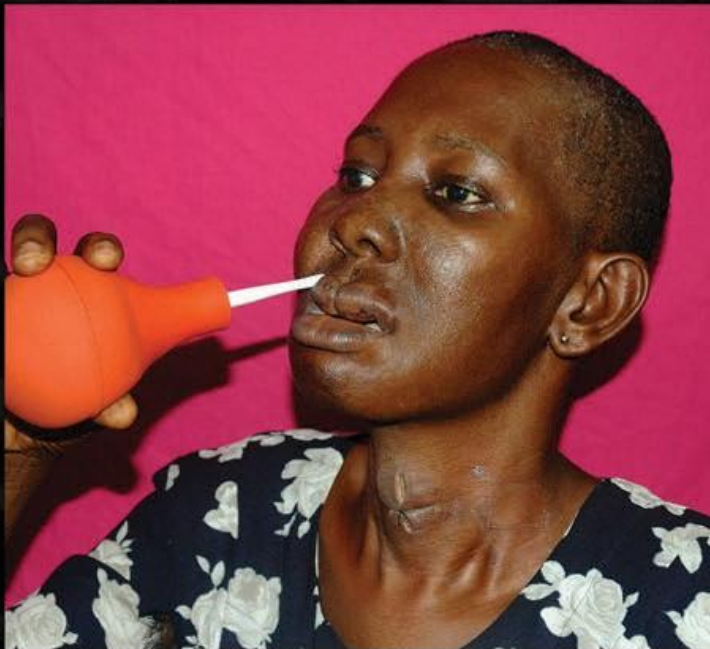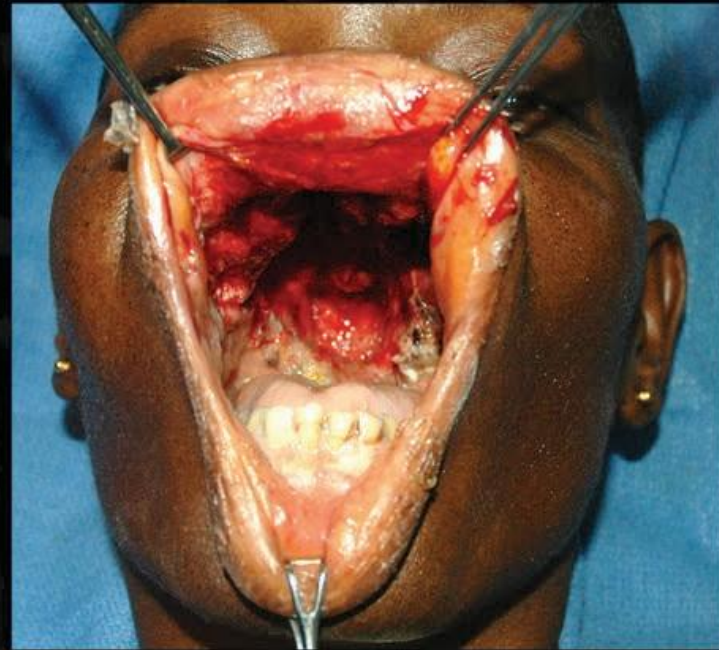
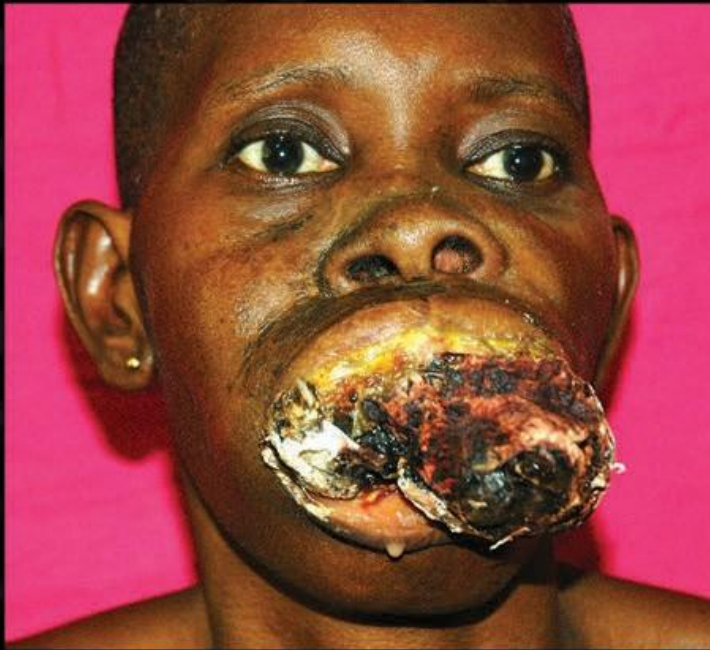# ifeoma

***"If it bleeds, kill it!"*** – Arnold Schwarzenegger, *Predator*

Ifeoma came to NCH in September 2012. She had a growth on her maxilla and we performed a partial maxillectomy. The pathology showed pleomorphic sarcoma. She needed radiation but, she disappeared.

In September 2013, she returned with a giant, fungating, bleeding mass growing from her remaining maxilla. The tumor appeared to swallow her face. We took her to surgery to see if the tumor was resectable. When I lifted her upper lip to see if it was attached to the tumor, she started to bleed uncontrollably. We were forced to act. We rapidly took a chisel and performed a total maxillectomy in minutes. We packed the wound and the bleeding stopped.

She healed nicely and we sent her for radiation. Unfortunately, we never saw her again.





# Hossana

***“When I looked around I saw and heard of none like me. Was I, then, a monster, a blot upon the earth from which all men fled and whom all men disowned?”*** – Mary Shelley, *Frankenstein*

Hossana came to see us in June, 2013. He had a huge mass on his neck that extended from the left lateral neck all the way around to his right posterior neck. The tumor was ulcerated and fixed to the surrounding tissues. It did not appear to be resectable. I suspected that he had metastatic nasopharyngeal cancer. I did a biopsy that showed squamous cell carcinoma. Squamous cell carcinoma (SCC) is an uncontrolled growth of abnormal cells arising in the squamous cells, which compose most of the skin's upper layers (the epidermis). I recommended radiation, but he refused.

Hossana came back to see me in October, 2013. The tumor was unchanged, but he appeared otherwise healthy. He was still working as a driver! I decided to operate.

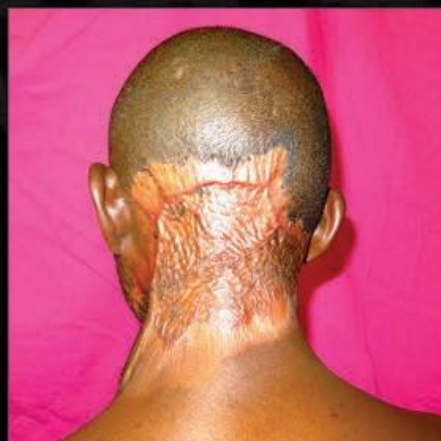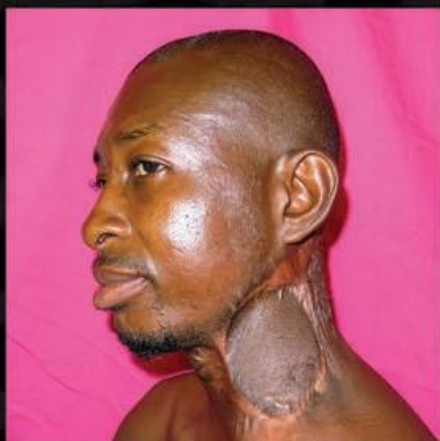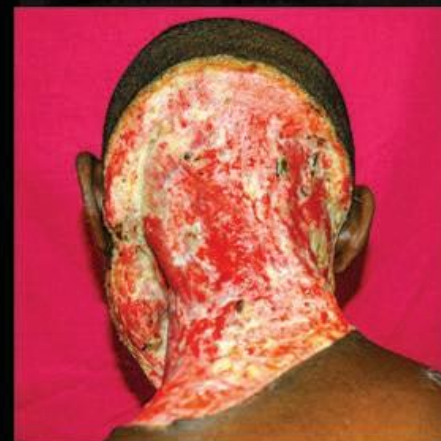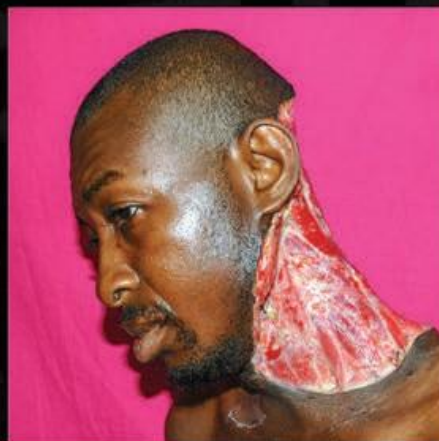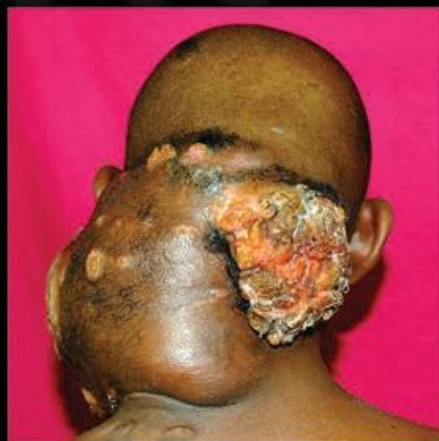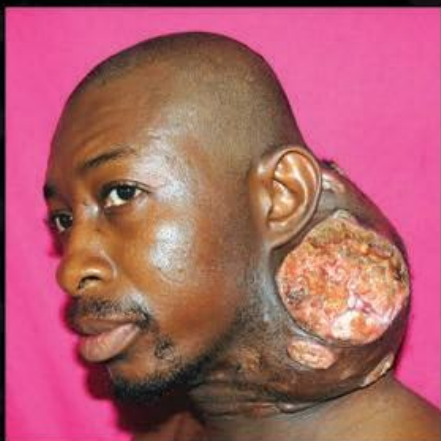The surgery was a bloodbath. We started on the right posteriorly and planned to move toward the left where the tumor overlaid the carotid artery and jugular vein. I planned to carefully control the blood loss, but everything we touched bled like crazy. Finally, we said, “Damn the torpedoes, full speed ahead,” and carved the tumor off Hossana's head as fast as possible. On the left side of the neck, we performed a radical neck dissection. We finally controlled the bleeding and quit for the day, leaving the wound open.

Every day, with a smile on his face, Hossana strolled down to the operating room for a dressing change. He never asked for pain medication. About one week later, we took him back to surgery and performed a pectoralis myocutaneous flap to cover his carotid artery.

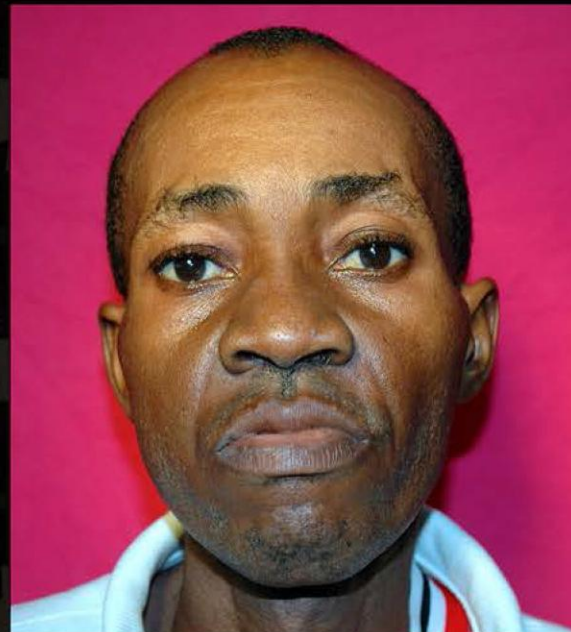
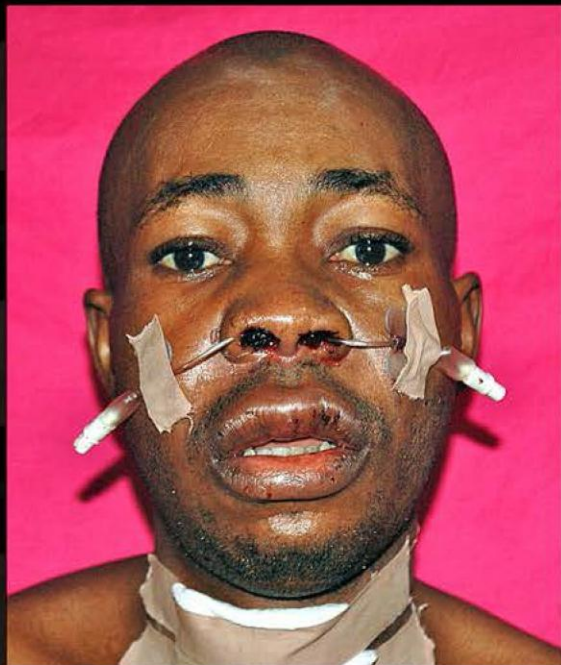
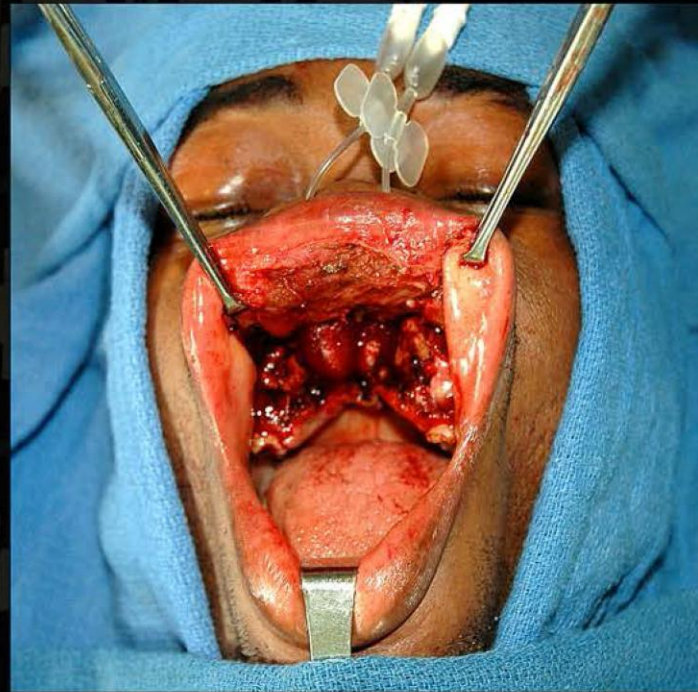
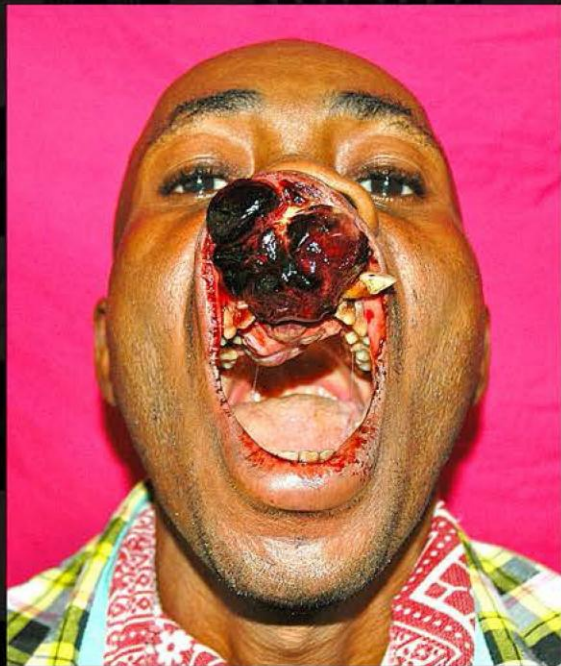I left him in the hands of Joy Nwookoma, our wound care nurse, until I returned in January of 2014. Joy did a great job, and the wound looked fantastic, perfect granulation tissue for a graft. Dr. Mishack Akunekwe performed a split thickness skin graft, and the wound healed fantastically. Hossana's pathology showed that his tumor was completely resected with no metastatic disease in 43 recovered lymph nodes.

When I saw Hossana the following year, he was cheerful as always. He had added quite a bit of weight and was healthy. We hope he is cured.











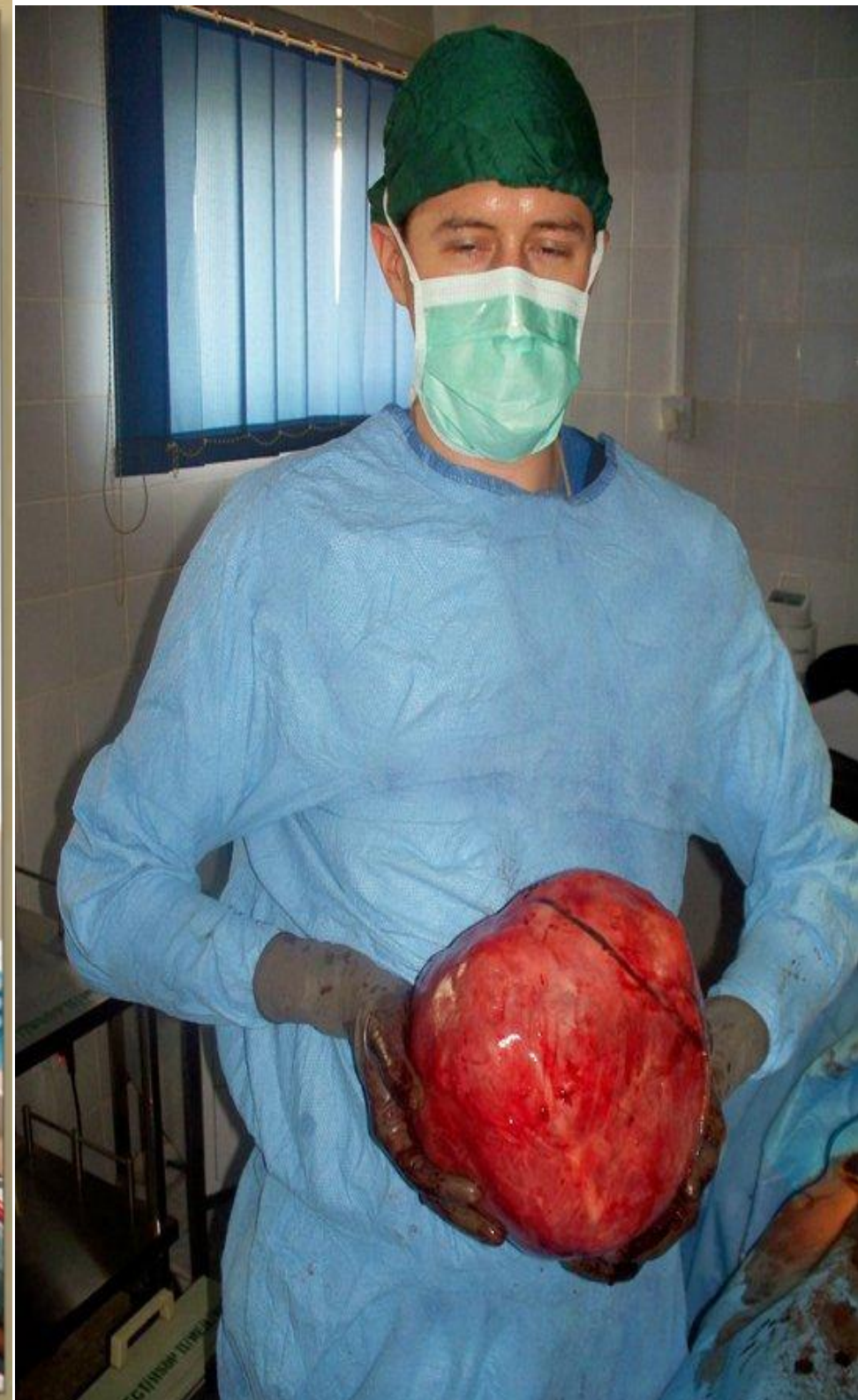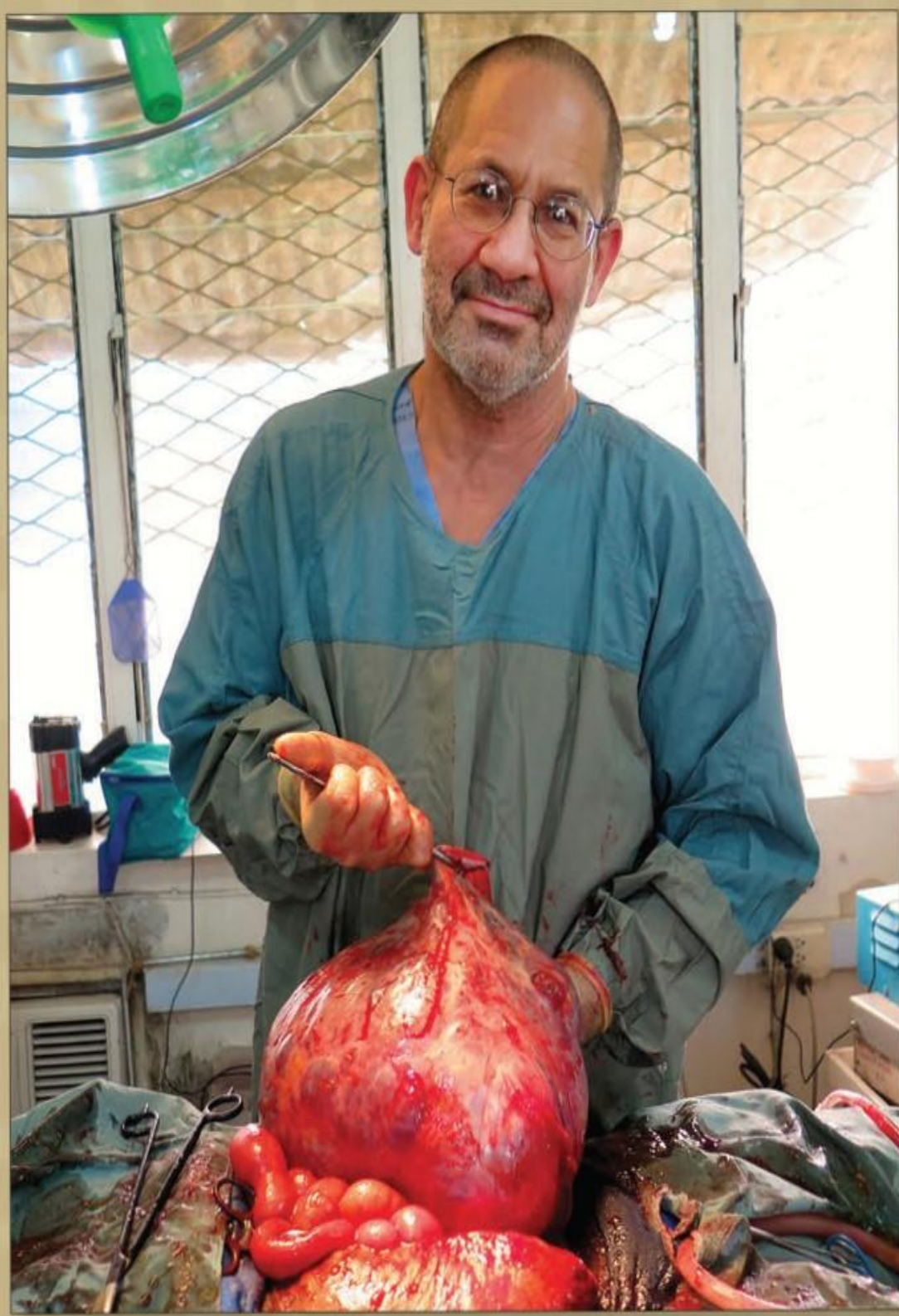chinedu

***"We don't know what it is, but it's the worst case we've ever seen."*** – Brian Camazine, MD

Chinedu is a 35 year-old male who came to the Nigerian Christian Hospital with a rapidly growing central maxillary mass that completely destroyed his midface tissues. We operated and performed a central maxillectomy. We had some ferocious bleeding from the nasal area, but this was nicely controlled with donated Rapid Rhino Nasal Packs. It turned out he also has AIDS. After surgery, we started him on retro-viral therapy and he is doing well. His pathology showed plasmablastic lymphoma, for which he is also receiving treatment. Lymphoma is not uncommon in AIDS patients.

Midface abnormalities are some of the most disturbing to humans since our brains love symmetry in the face. An abnormality in this location immediately focuses our attention to the problem like a moth to light. This partially explains why patients with these problems, often become pariahs in their villages.







# chingere

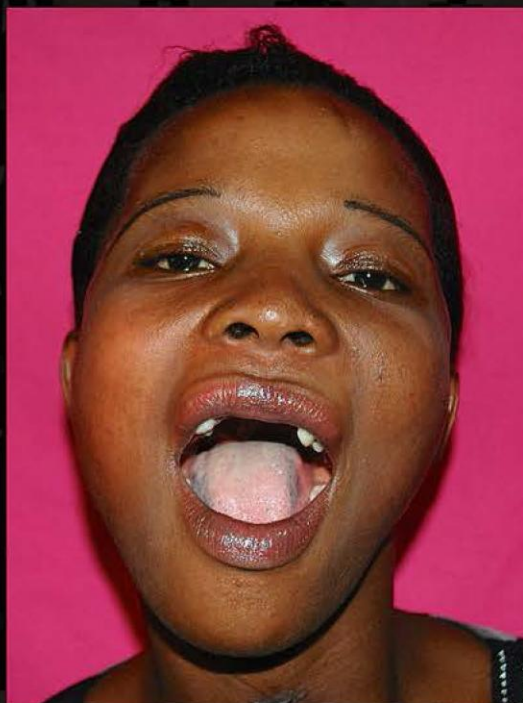
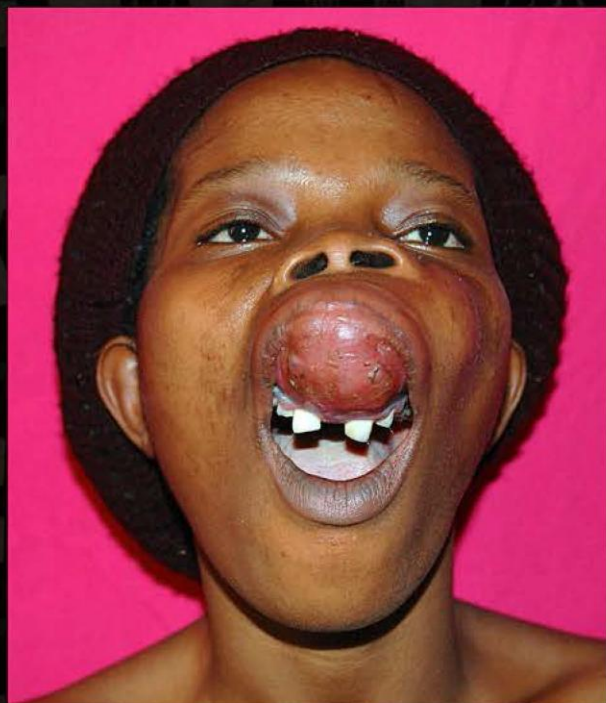***"I prefer to believe the opposite - that there is always an indestructible beauty at the heart of darkness."***

— Mary Balogh — *'A Secret Affair'*

Chingere presented with a maxillary mass that had been growing for several years. There was some destruction of the hard palate with loosening of the front teeth. The mass felt solid, but soft. We operated and found a giant cystic mass full of thick fluid that had destroyed part of the maxilla and palate. The lesion appeared to be benign. We drained the cyst and completely removed the lining of the maxillary sinus. The pathology showed possible ameloblastoma.

I could not believe how beautiful she was when she returned for a checkup!





# godstime

***"A small body of determined spirits fired by an unquenchable faith in their mission can alter the course of history."***

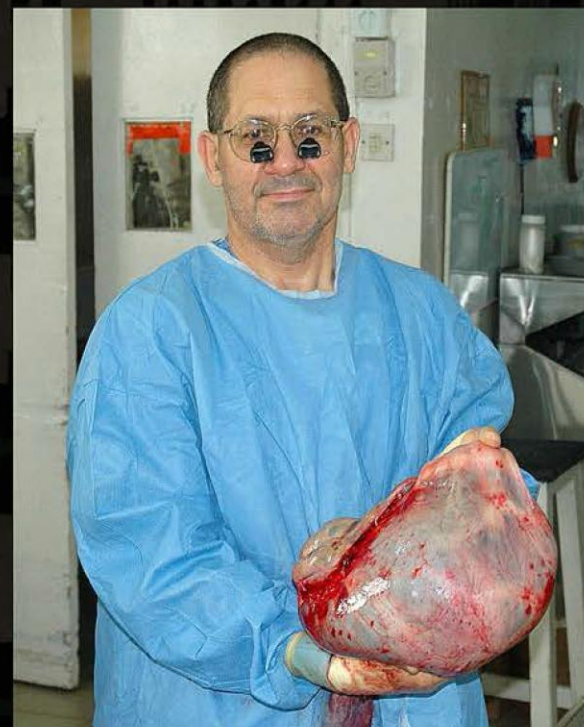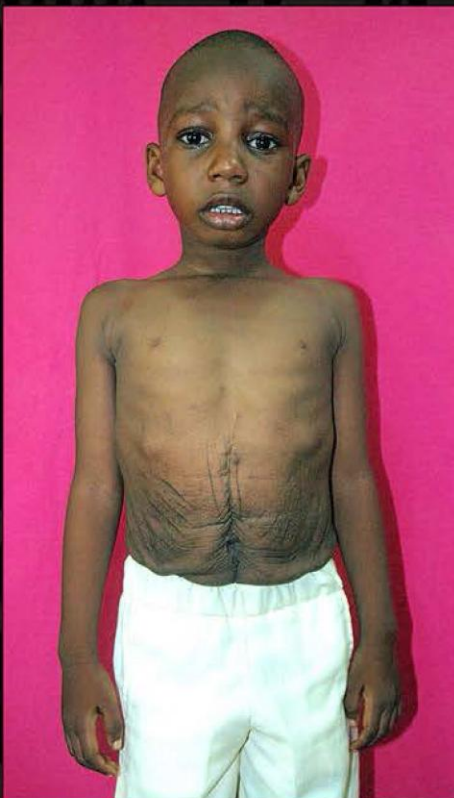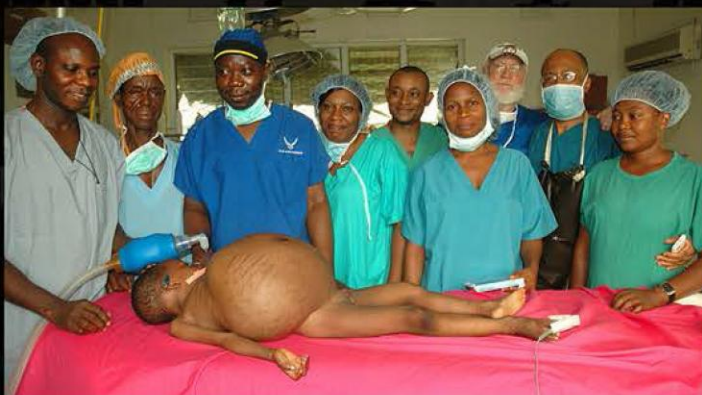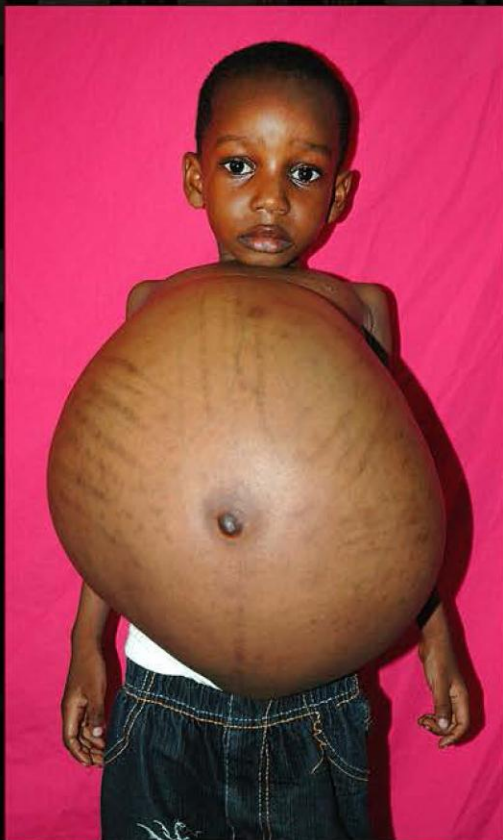– Gandhi

Godstime had been developing an abdominal mass since birth. After seeking treatment at several medical centers, his parents brought him to NCH. The mass was so large that Godstime could barely eat. We didn't know what he had, but it was the worst case we had ever seen!

We operated the next day with a large team of people assisting. We found a giant, cystic kidney that we removed without difficulty. Godstime made a slow recovery and left the hospital in ten days.

After six months, Godstime and his father returned for a checkup. They were both wearing white suits and were dashing in their sartorial splendor. His father was so happy and thankful that he could not speak without crying.







# keziah

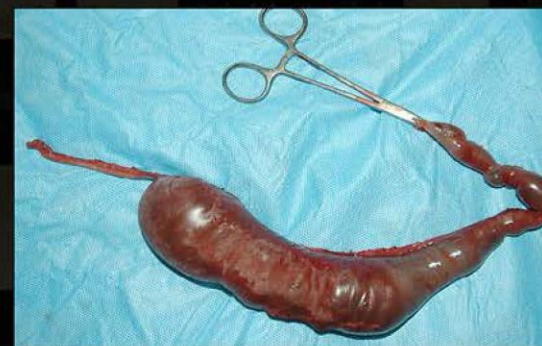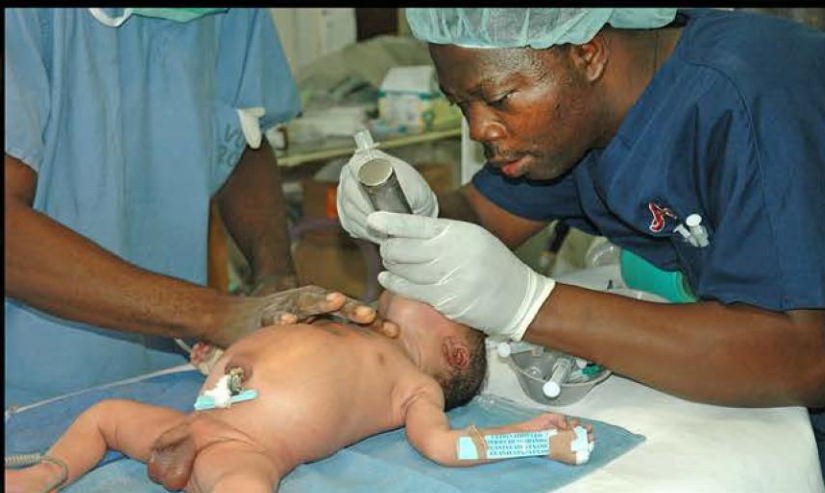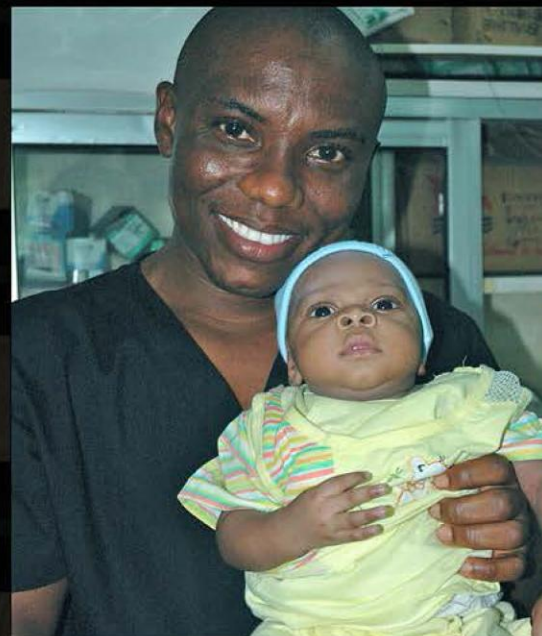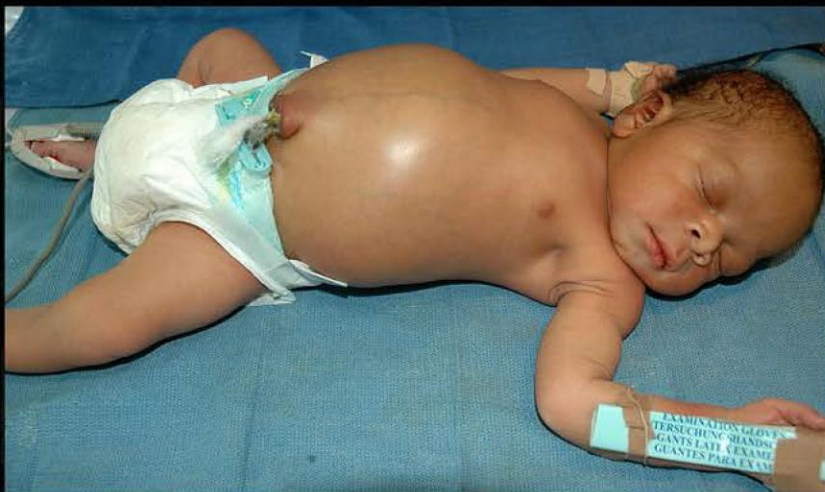***"If I had my life to live over again, I'd be a plumber."*** – Albert Einstein

This little baby was one week old when he was brought to the hospital. His abdomen was distended and he clearly had a bowel obstruction. It was obvious that we would have to operate – no small feat with a small, dehydrated baby. I called Eric Oje, our nurse anesthetist and explained the situation. As usual, he was calm and collected despite the critical situation. In minutes, the baby was asleep and ready for surgery.

We opened the abdomen and found a jejunal atresia – a blockage where a part of the intestine failed to develop, causing an obstruction-similar to a plugged pipe. Proximal to the obstruction, the normal bowel dilates. We resected the bad section and prayed that the baby had enough physical reserve to recover.

In about five days, the baby was eating and having bowel movements. The mother was so excited, as were we.





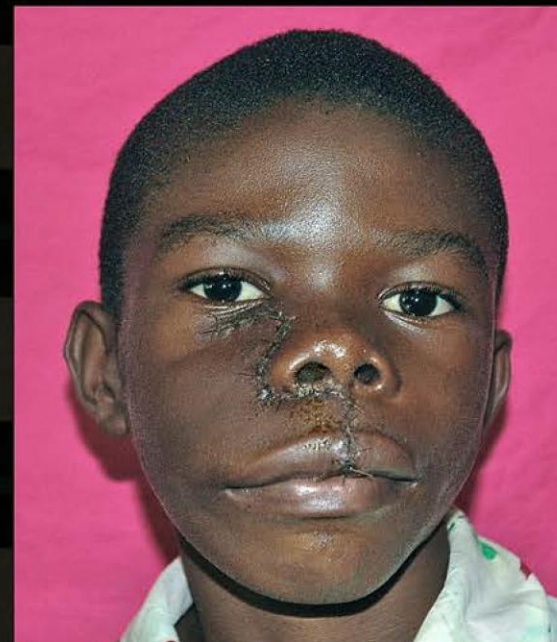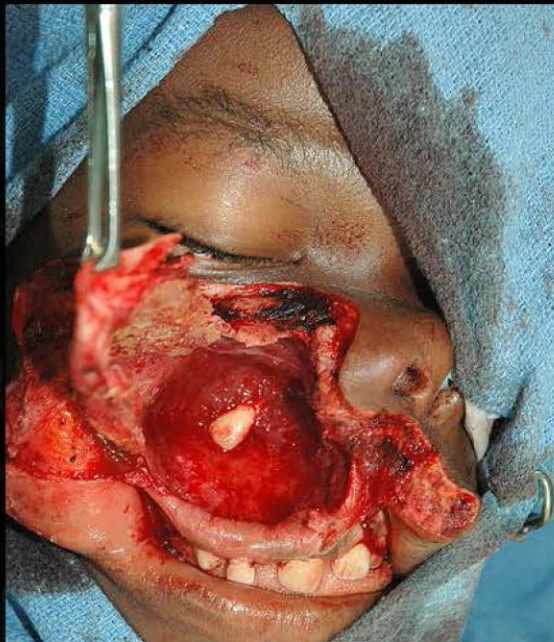
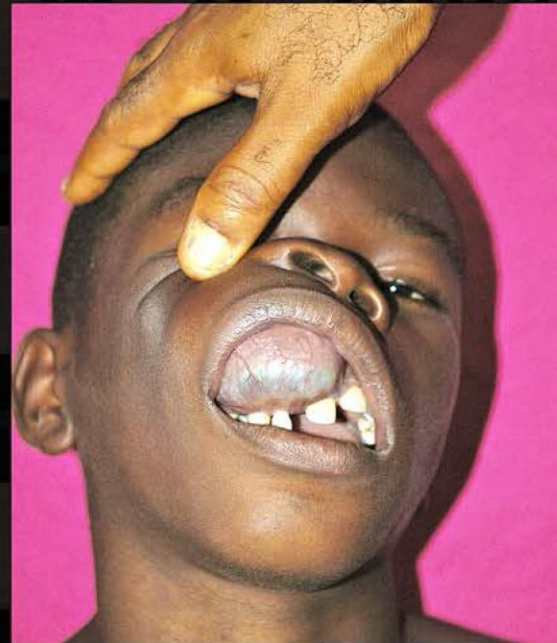
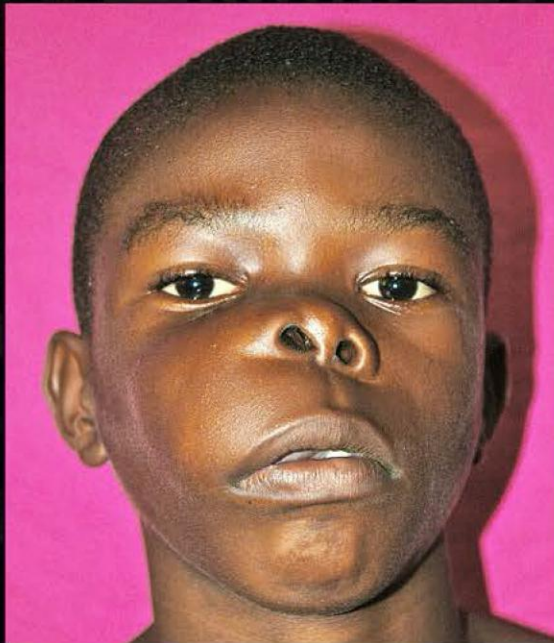
chukwu

***“No, my friend, I am not drunk. I have just been to the dentist, and need not return for another six months! Is it not the most beautiful thought?-Poirot” – Agatha Christie – One, Two, Buckle My Shoe***

Chukwu came to NCH with a maxillary swelling. The mass felt somewhat cystic and had destroyed the inferior and anterior walls of the maxillary sinus and displaced many of the adjacent teeth.

At surgery, we found an ectopic tooth – this was a dentigerous cyst! Chukwu had an uneventful recovery and a good cosmetic result.







ngozi

***Composite: A conceptual whole made up of complicated and related parts.***

Ngozi first came to the NCH in September, 2011. She was waiting for me when I arrived. A 'Camazine case.' I had heard rumors, before leaving the USA, that there was a patient waiting for me with a large, recurrent spindle cell sarcoma of the shoulder.

She had four surgeries in the past, the last approximately 1.5 years before I met her. She had no evidence of metastatic disease so we decided to do a radical resection of the tumor.

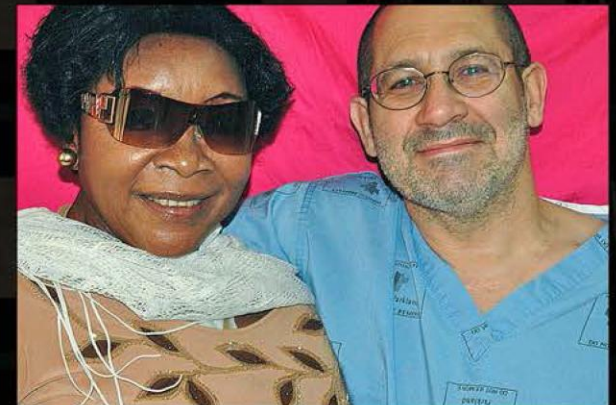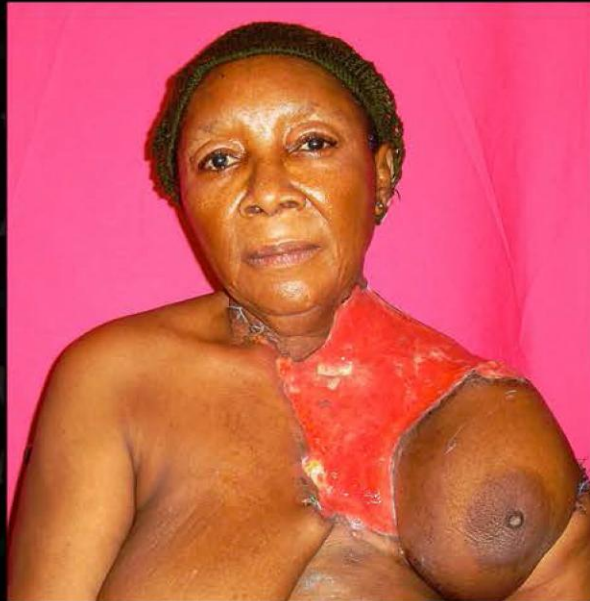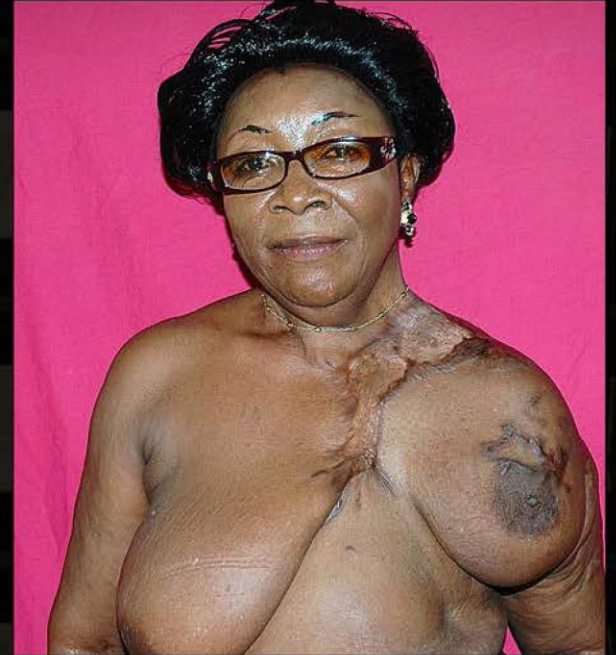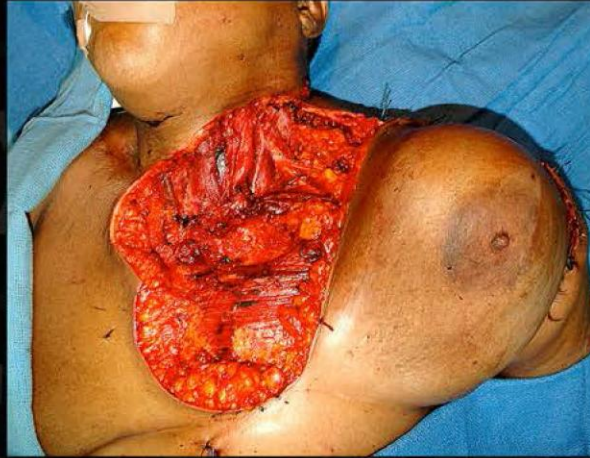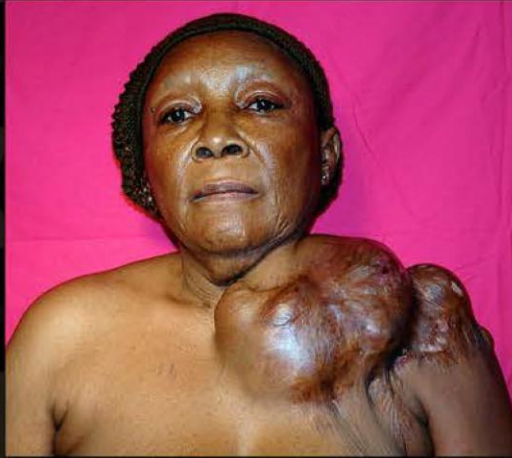The surgery was quite dramatic. We had to remove all the skin that was involved including the upper breast, perform a radical neck dissection, as well as remove the clavicle, the upper portion of the pectorals major muscle, the deltoid muscle and part of the trapezius muscle. The capsule of the shoulder joint was completely exposed. We had a big hole! Using a somewhat radical solution, we mobilized the remaining breast, removed most of the breast tissue and used the resulting skin as a cutaneous flap. Part of the wound was left open for a delayed skin graft. Ngozi slowly improved and her wound started granulating. After I returned to the USA, Dr. Mike Enyinnah did a skin graft to the remaining open areas.

Ngozi has recovered quite well. Not unexpectedly, she has some decreased motion in her left arm, but this is improving. We may do more cosmetic surgery to the breast area in the future. Perhaps because of the lymphatics in the breast, there is no swelling in the arm.

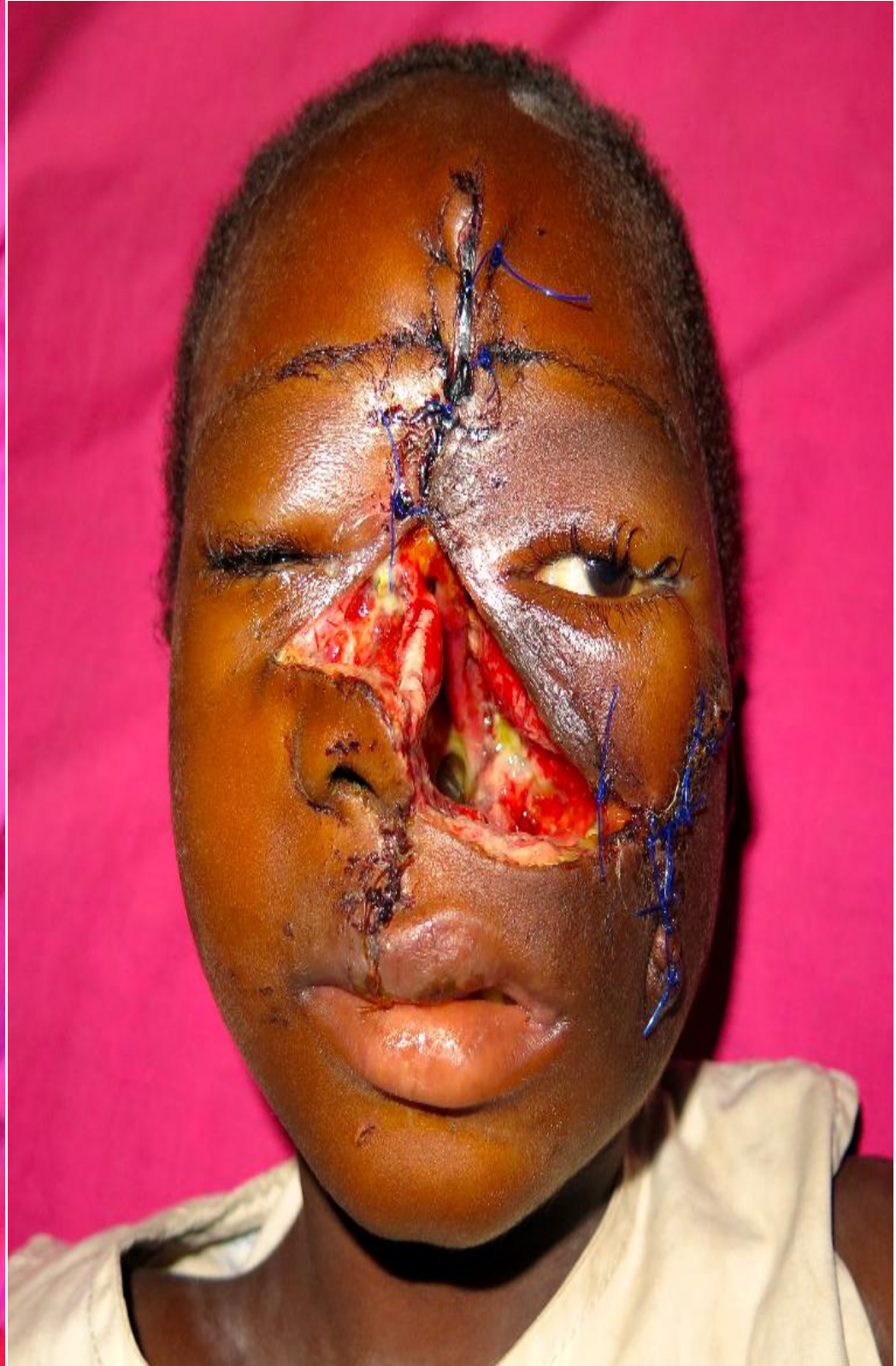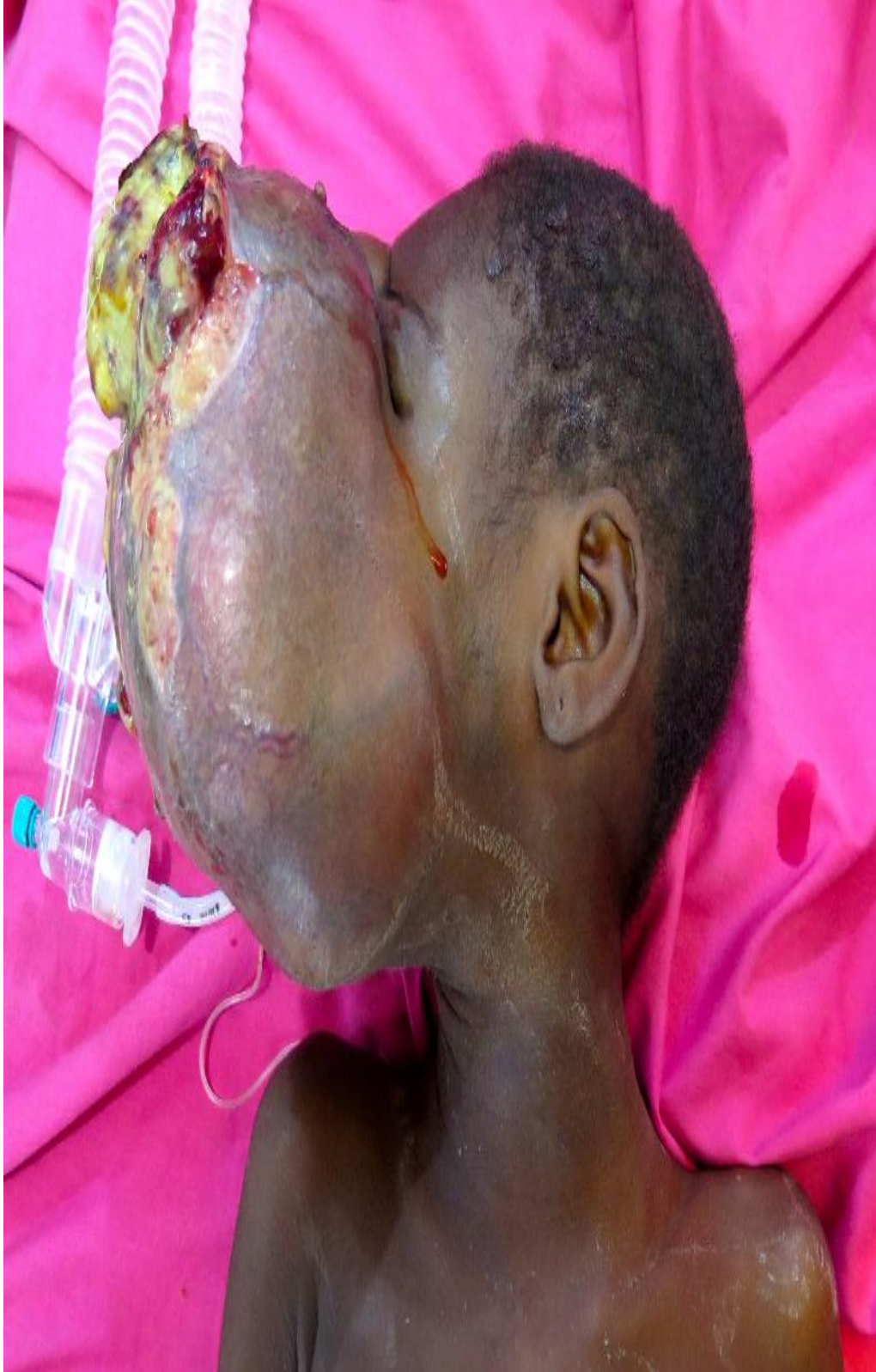The greatest shock of this case was the pathology report from my friend, Dr. Danny Milner, at Harvard University. Ngozi does not have a sarcoma! She has a dermatofibrosarcoma protuberans, a 'benign tumor' that can be very locally aggressive. Unfortunately, we have often found that pathology from Nigeria is not reliable.

Ngozi and I have become great friends. She visits me every time I come to Nigeria and brings me fruits and vegetables.

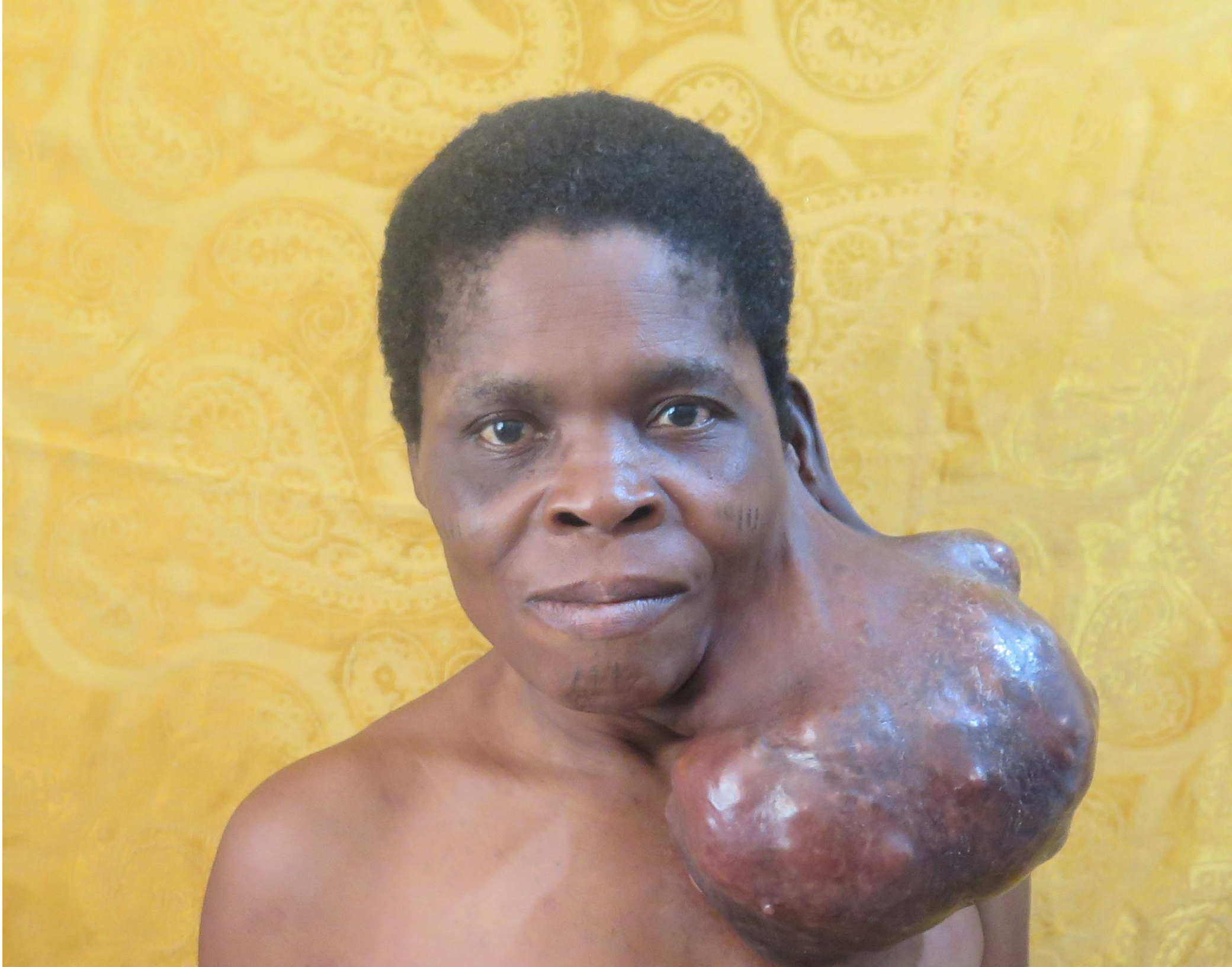














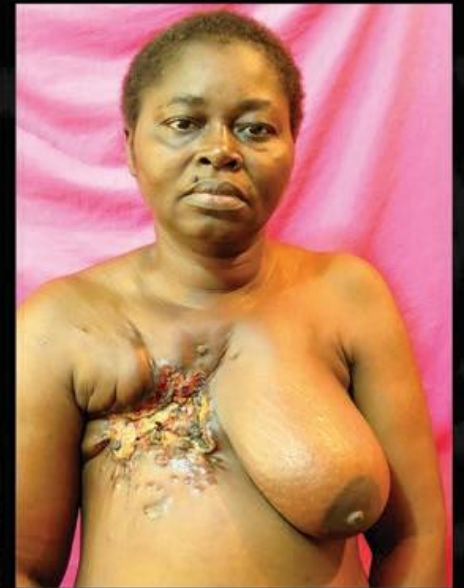
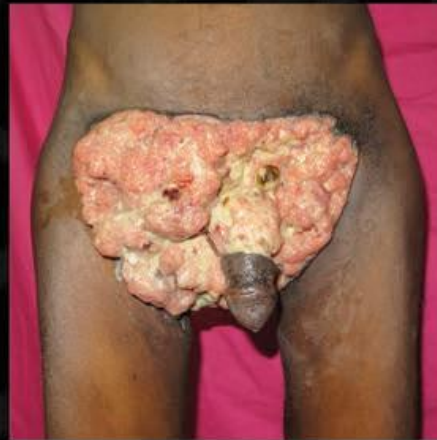
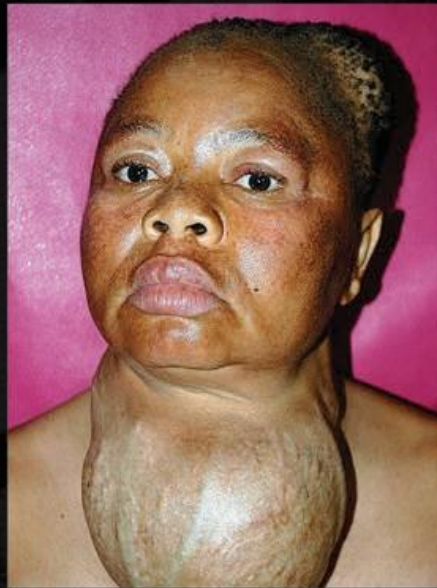
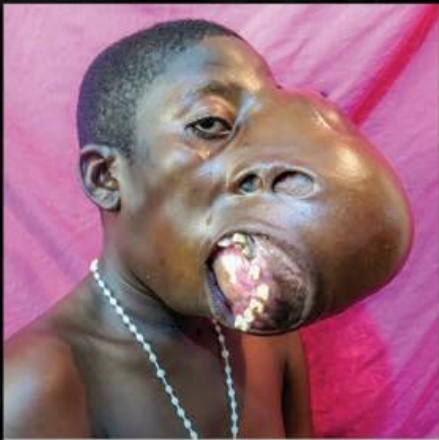
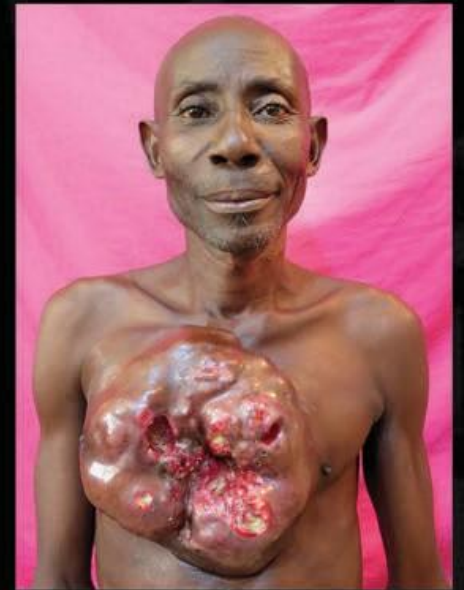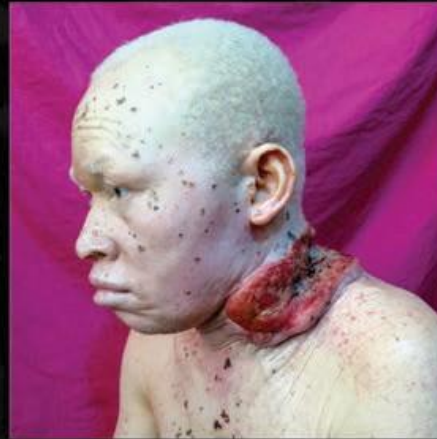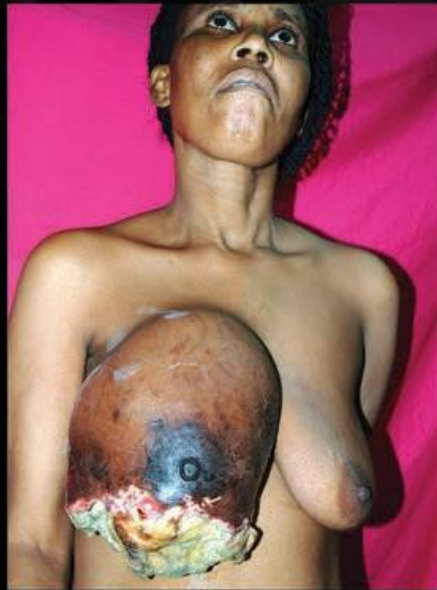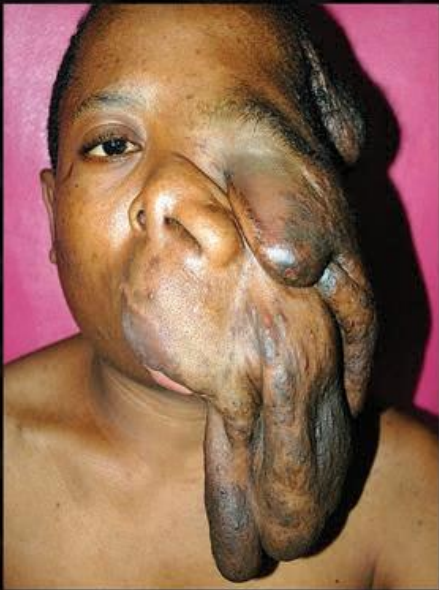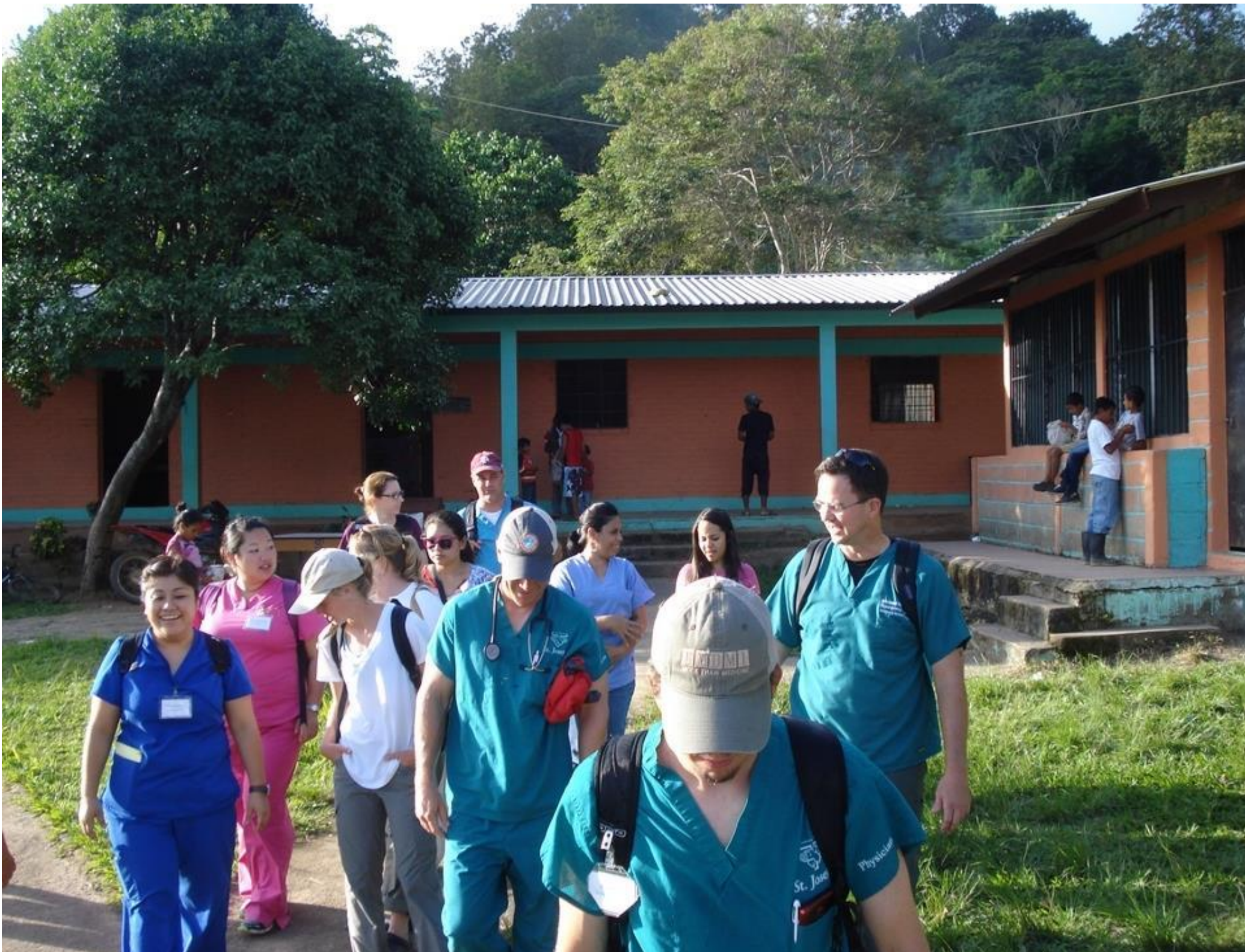# *those beyond help*

These poor souls are some of those we could not help; patients whose disease was so advanced that we had no treatment or patients who disappeared after their initial consultation because they were too scared or had lost all hope.

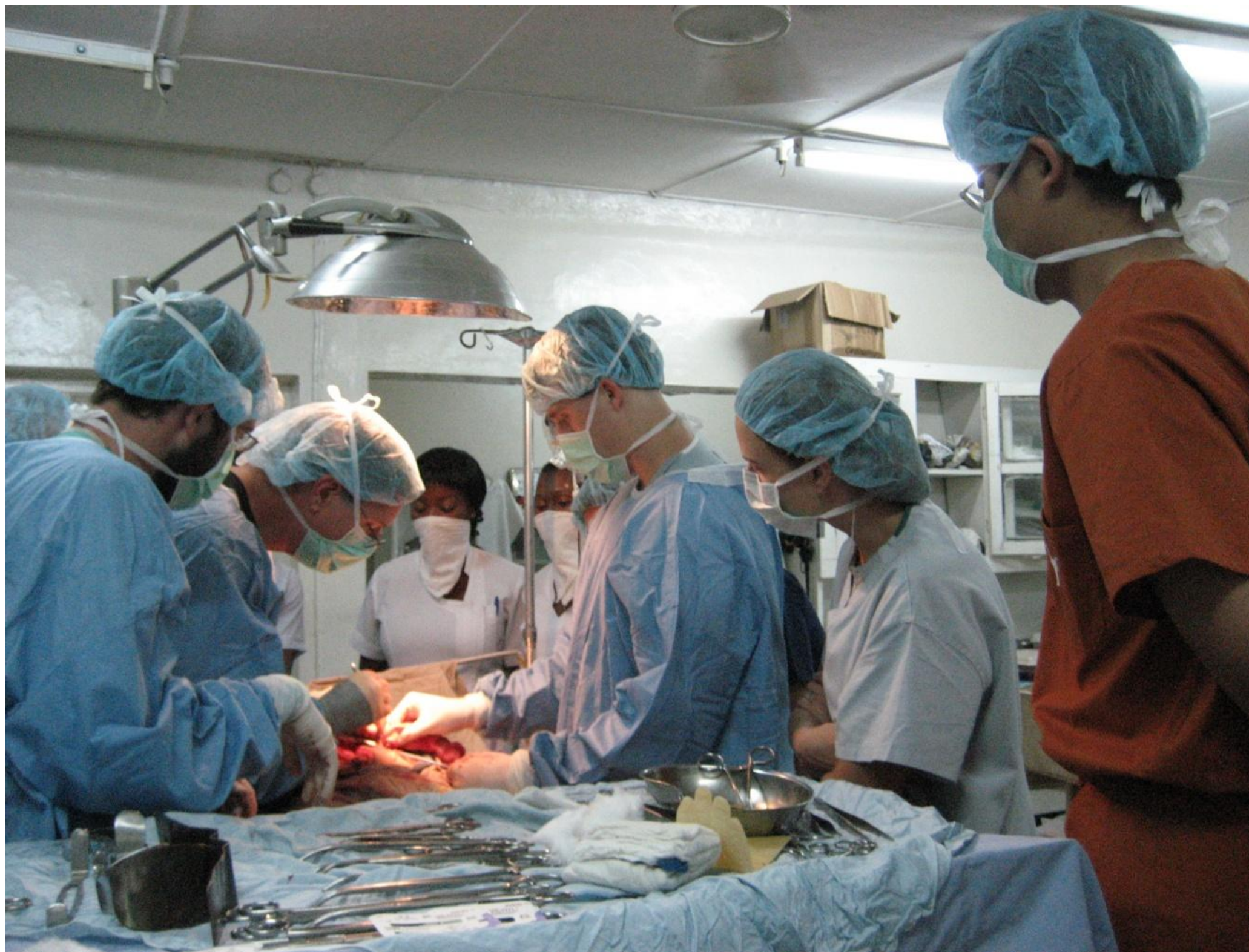Sometimes, all we can give our patients is a caring touch and a prayer.





















***"My religion is very simple. My religion is Kindness." – Dalai Lama***



## **HUMANITARIAN ORGANIZATION OF THE YEAR 2013**

**BY- THE GLOBAL THINKERS FORUM LONDON UNDER THE AUSPICES OF CITY OF ATHENS, GREECE**

**Our work is driven by volunteers-Please join us today!!!**

## **DIRECTORS**

<b>Mrs. Reem N. Bissio</b>	<b>Chair-</b>	<b>Jordanian</b>
<b>Mr. Gbemuotor Kama.</b>		<b>Nigerian</b>
<b>Prof. Gbaranen Gbaanador</b>		<b>American</b>
<b>Mr. Cliff H. Jarrell.</b>		<b>American</b>
<b>Mr. Markus von-Have.</b>		<b>German</b>
<b>Prof. Brian Camazine.</b>		<b>American</b>
<b>Ms. Melina Mesanovic.</b>		<b>Serbian</b>
<b>Mrs. Angela C. Johnson.</b>		<b>American</b>
<b>Dr. Conrado Ordonez.</b>		<b>American</b>
<b>Dr. Lorinda Liang</b>		<b>American</b>

## **ADVISORY BOARD**

<b>Prof. Stuart Quartemont</b>	<b>Chair</b>	<b>American</b>
<b>Ambassador Joe Ayalogu</b>		<b>Nigerian</b>
<b>Ms. Jutta Wisura</b>		<b>German</b>
<b>Dr. Philip Eze</b>		<b>Nigerian</b>
<b>Mr. Yaron Aharon</b>		<b>Israeli</b>
<b>Dr. Marcie Russell</b>		<b>Jamaican</b>
<b>Mr. Olayinka Ajiboye</b>		<b>Nigerian</b>
<b>Mr. Orson Nurse</b>		<b>American</b>
<b>Mr. Hermant Patwari</b>		<b>Indian</b>
<b>Ambassador S. Parker Allotey</b>		<b>Ghanaian</b>
<b>Ms. Anita Singh</b>		<b>Nepalese</b>

## **PROFOH NIGERIA BOARD**

<b>Dr. Safiya Umar</b>	<b>Chair</b>	<b>Nigerian</b>
<b>Mr. Olayinka Ajiboye</b>		<b>”</b>
<b>Dr. Prosper Ahwerogba</b>		<b>”</b>
<b>Barr. Victor Opurum</b>		<b>”</b>
<b>Mr. Mohammed L. Shuibu</b>		<b>”</b>
<b>Barr. Clara Ndiva</b>		<b>”</b>
<b>Dr. Philip Eze</b>		<b>”</b>